Basic & Advanced Airway Management

Aaron J. Katz, AEMT-P, CIC

2011 Version

www.es26medic.net

Topics

- Respiratory Problems
- Respiratory System Assessment
- Airway Management

Quick Review of Respiratory A&P

Figure 3-98 Anatomy of the upper airway.

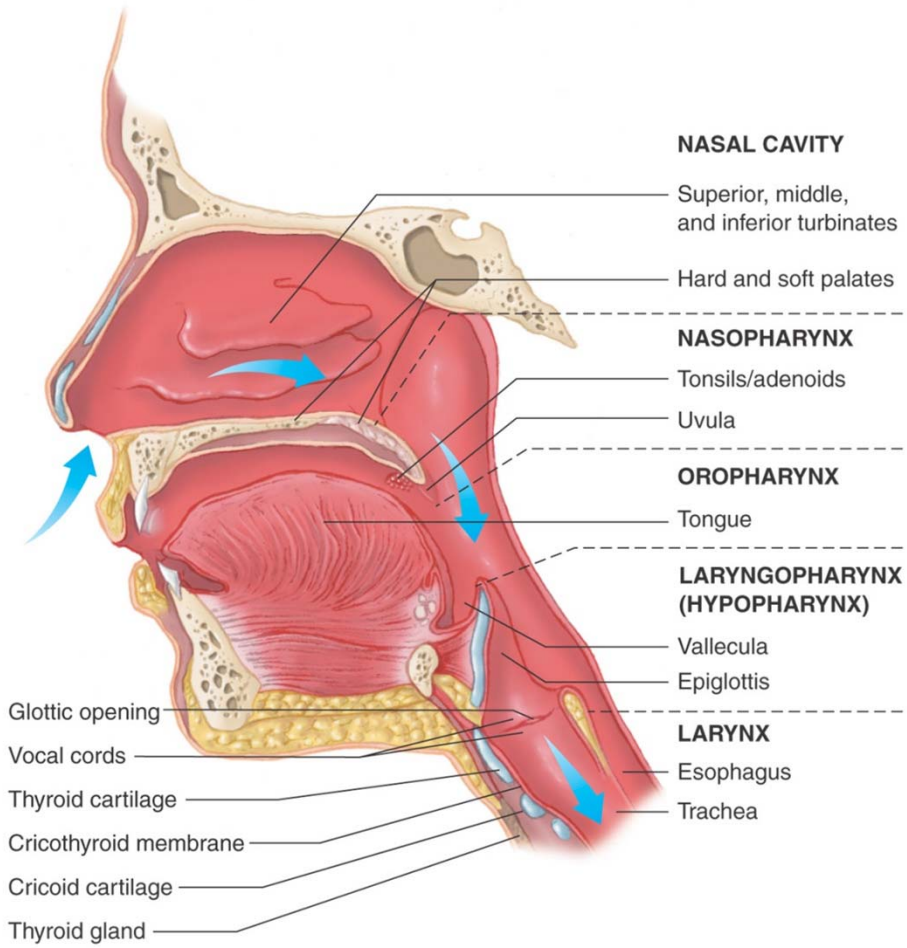

Figure 3-99 Internal anatomy of the upper airway.

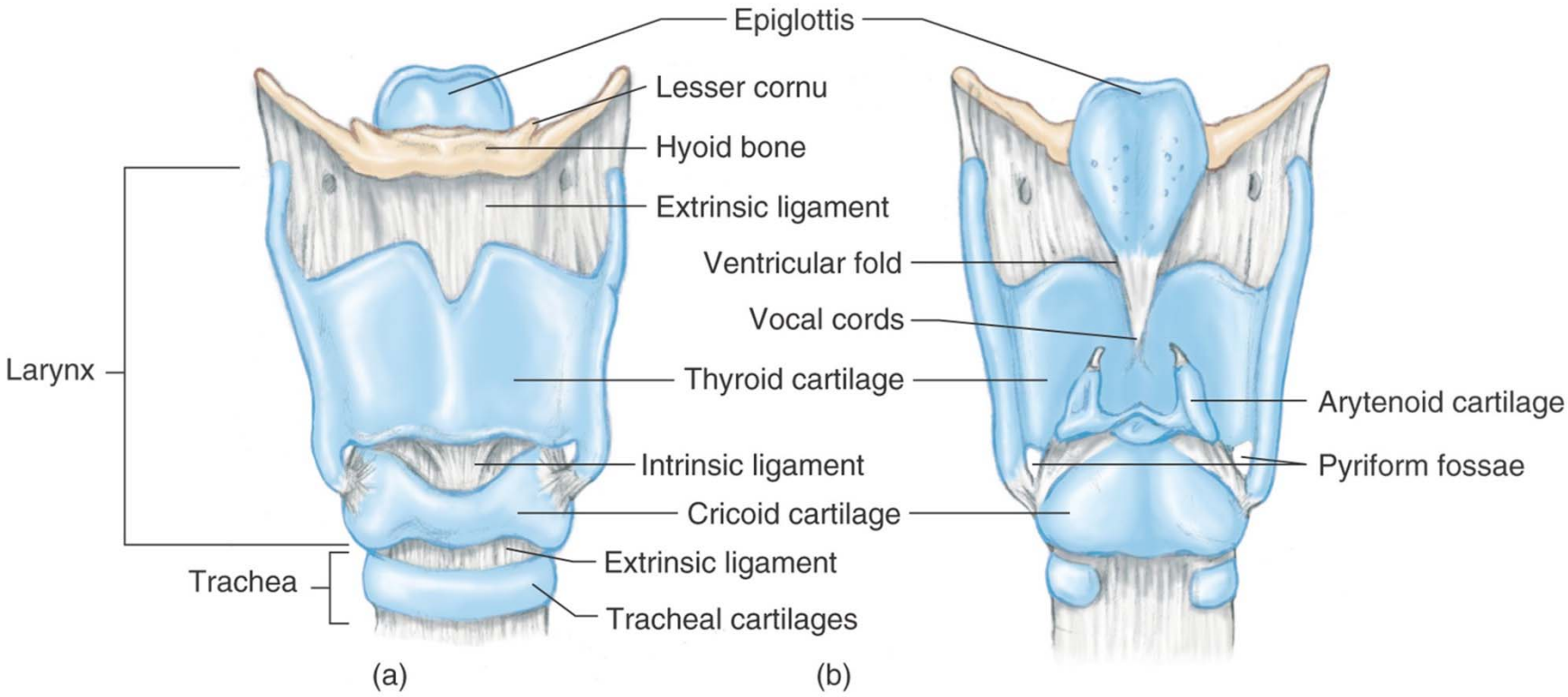

Figure 3-100 Anatomy of the lower airway.

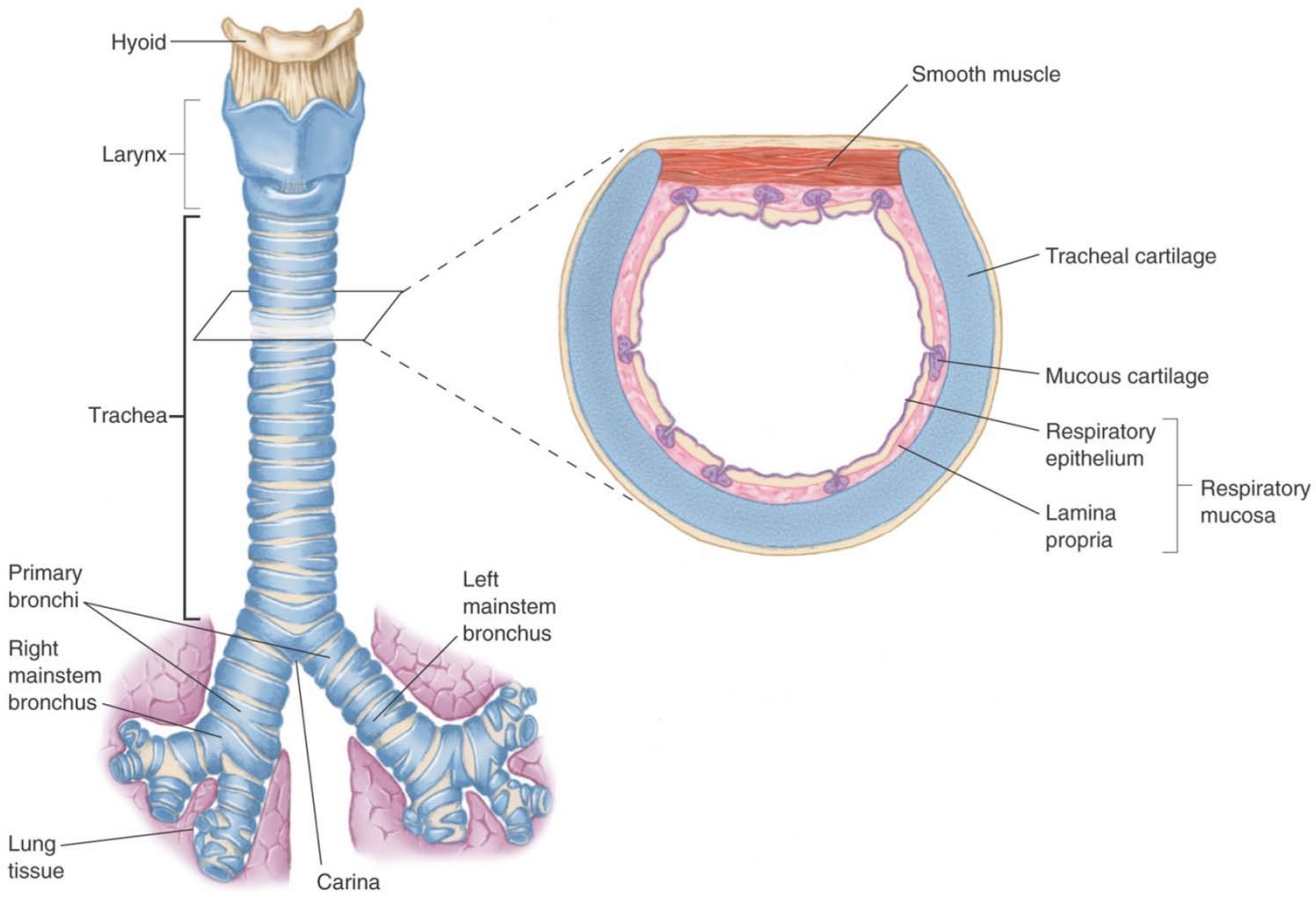

Figure 3-101 Anatomy of the alveoli.

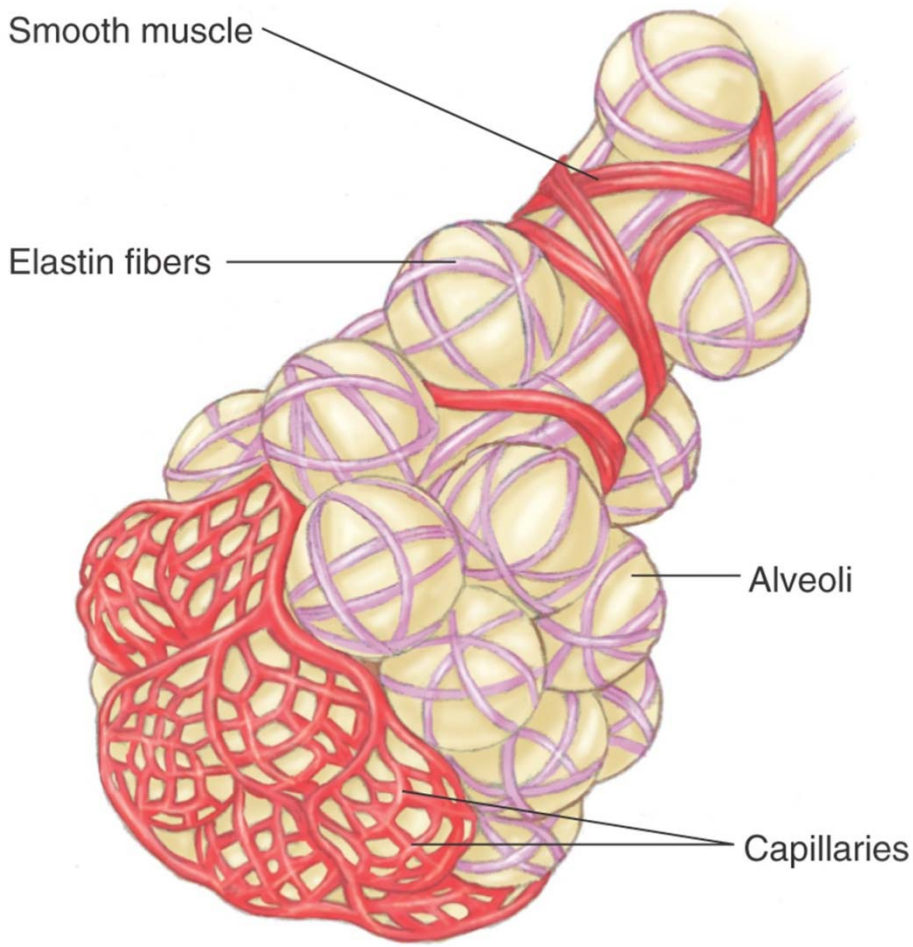

Figure 3-102 Anatomy of the pediatric airway.

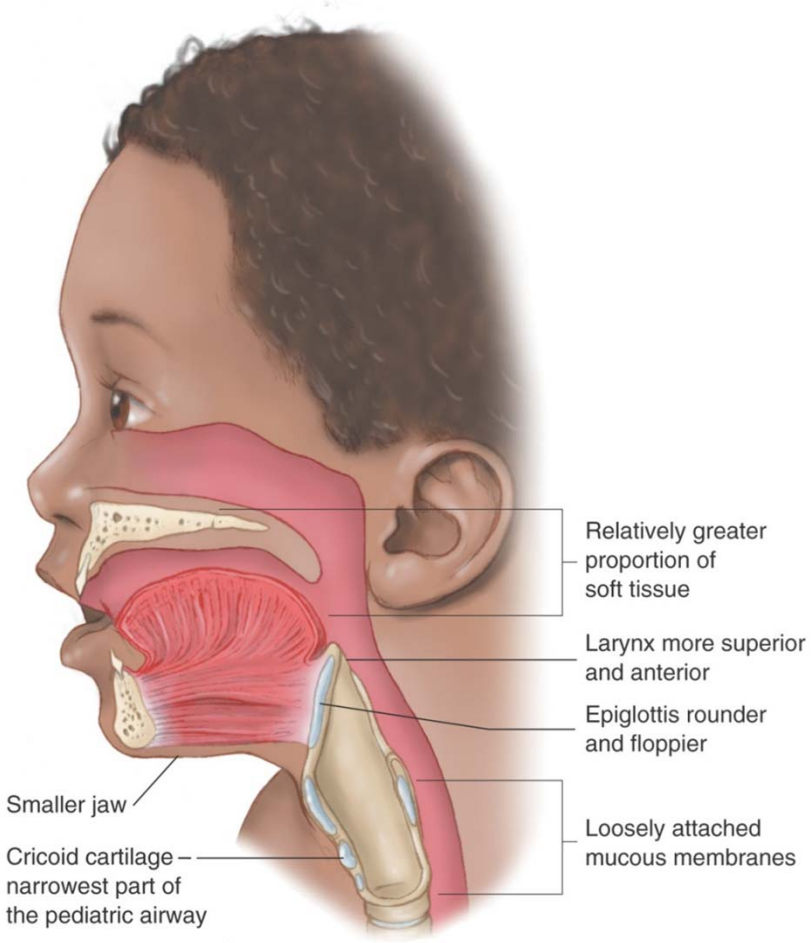

Figure 3-103 Diffusion of gases across an alveolar membrane.

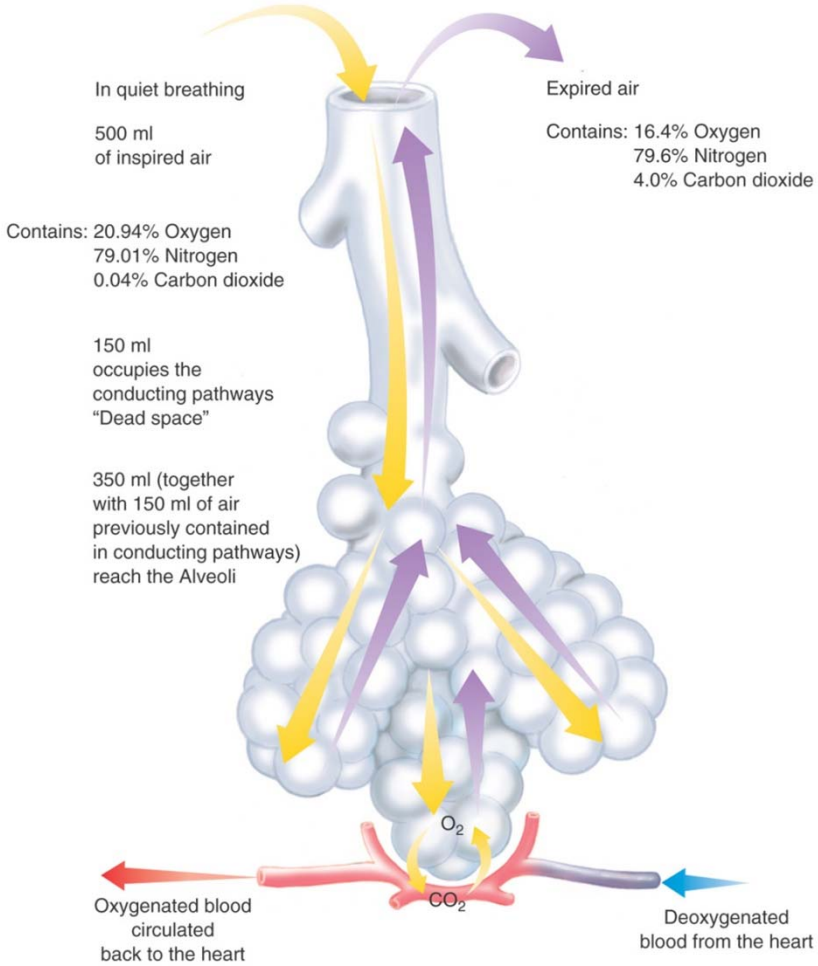

Figure 8-31 Glottis visualized through laryngoscopy.

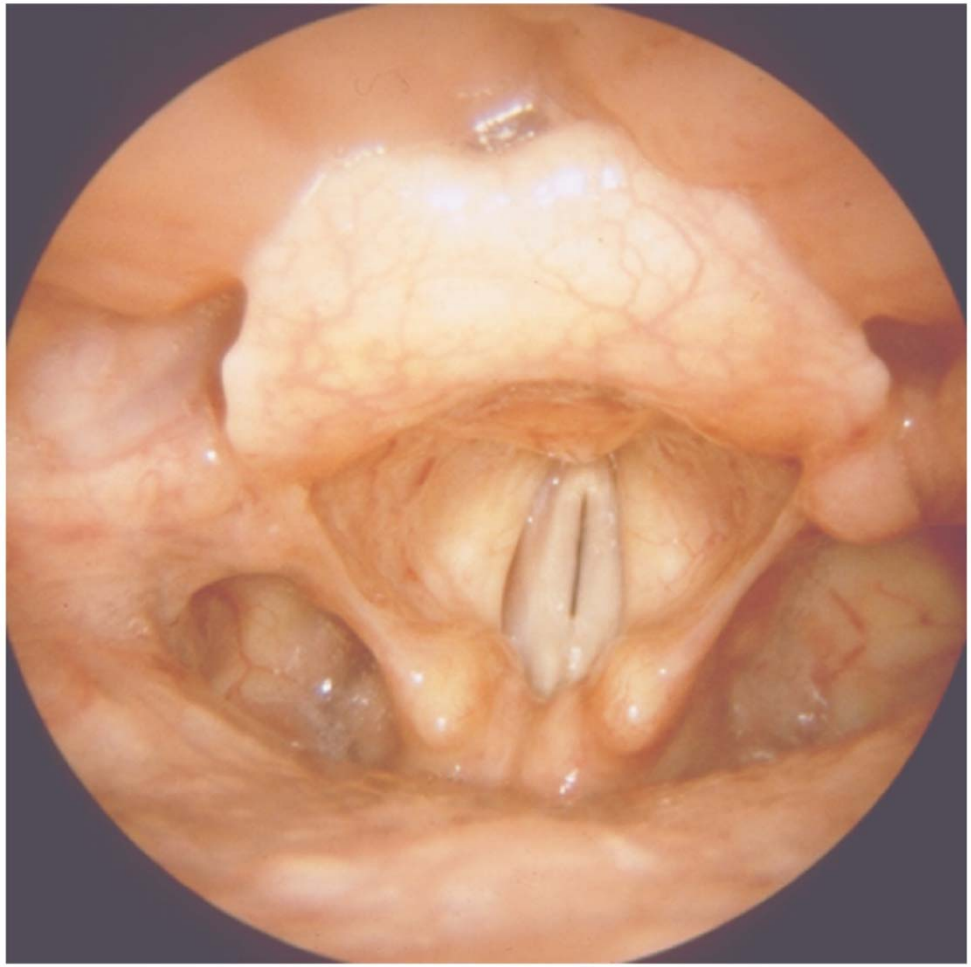

Respiratory Problems

Airway Obstruction

- The tongue is the most common cause of airway obstruction.

The tongue as an airway obstruction

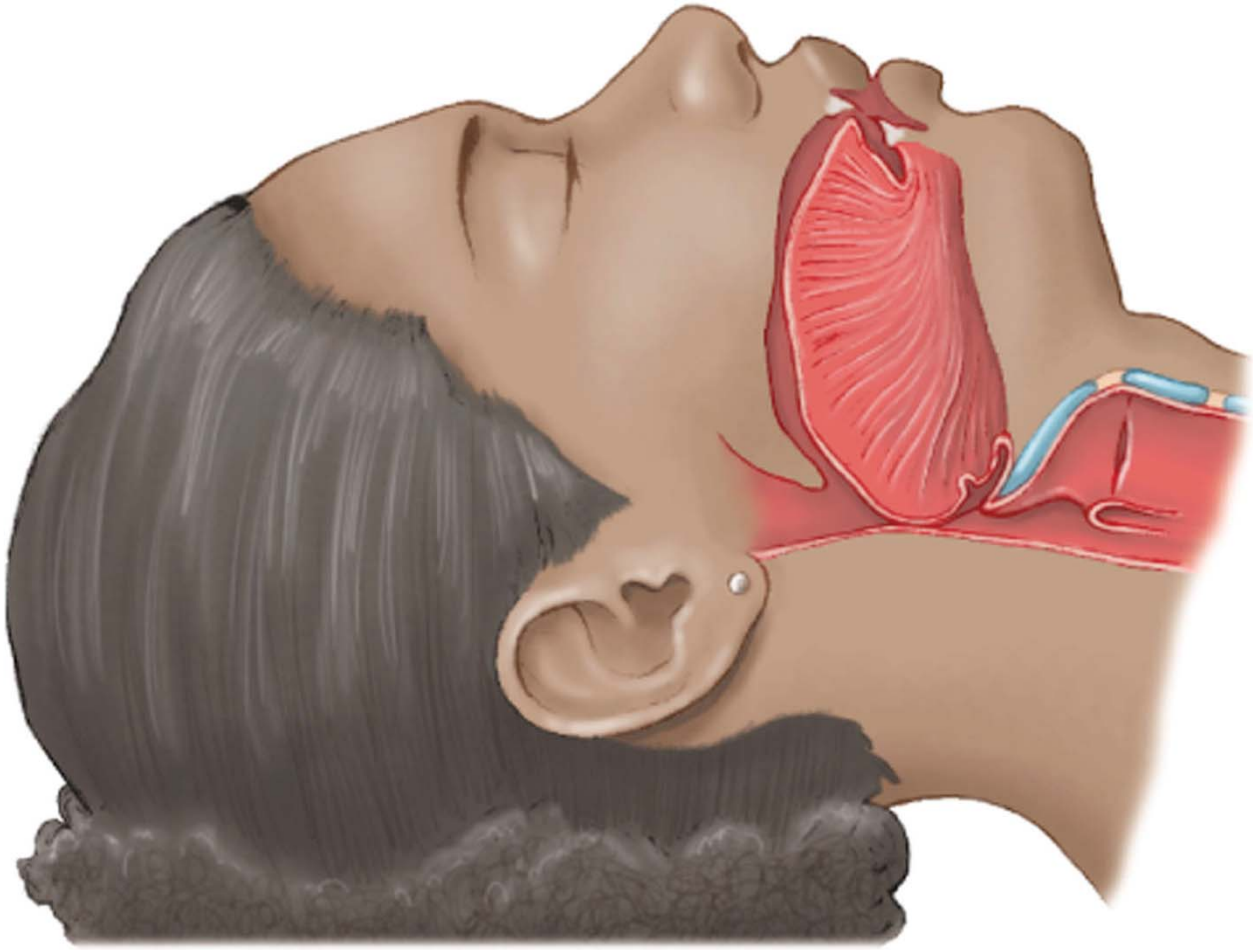

Inadequate minute volume respirations can compromise adequate oxygen intake and carbon dioxide removal.

Other Causes of Airway Obstruction

- Foreign bodies
- Trauma
- Laryngeal spasm and edema
- Aspiration

Respiratory System Assessment

Initial Assessment

- Is the airway patent?
- Is breathing adequate?
- Look, listen, and feel.
- If patient is not breathing, open the airway and assist ventilations as necessary.

Feel for air movement.

Look for chest movement.

Listen for air movement.

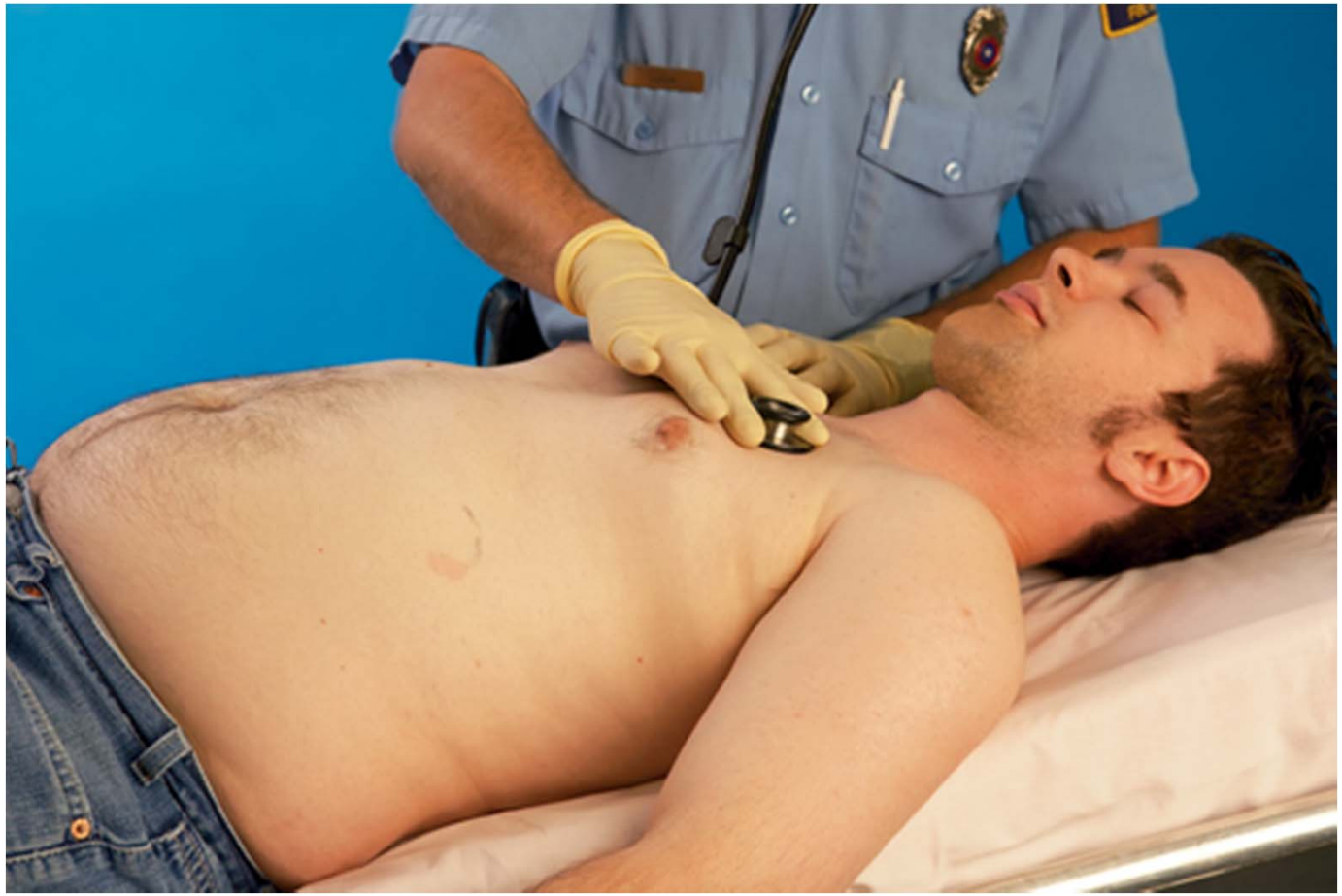

Bag-valve-mask ventilation

Focused History

- Onset
- Symptom development
- Associated symptoms
- Past medical history
- Recent history
- Does anything make symptoms better or worse?

Physical Examination

Inspection

- Skin color
- Patient's position
- Dyspnea
- Modified forms of respiration
- Rate
- Pattern
- Mentation

Abnormal Respiratory Patterns (1 of 3)

- Kussmaul's respirations
  - Deep, slow or rapid, gasping; common in diabetic ketoacidosis
- Cheyne-Stokes respirations
  - Progressively deeper, faster breathing alternating gradually with shallow, slower breathing, indicating brain stem injury

Abnormal Respiratory Patterns (2 of 3)

- Biot's respirations
  - Irregular pattern of rate and depth with sudden, periodic episodes of apnea, indicating increased intracranial pressure
- Central neurogenic hyperventilation
  - Deep, rapid respirations, indicating increased intracranial pressure

Abnormal Respiratory Patterns (3 of 3)

- Agonal respirations
  - Shallow, slow, or infrequent breathing, indicating brain anoxia

Auscultation

- Listen at the mouth and nose for adequate air movement.
- Listen with a stethoscope for normal or abnormal air movement.

Positions for auscultating breath sounds

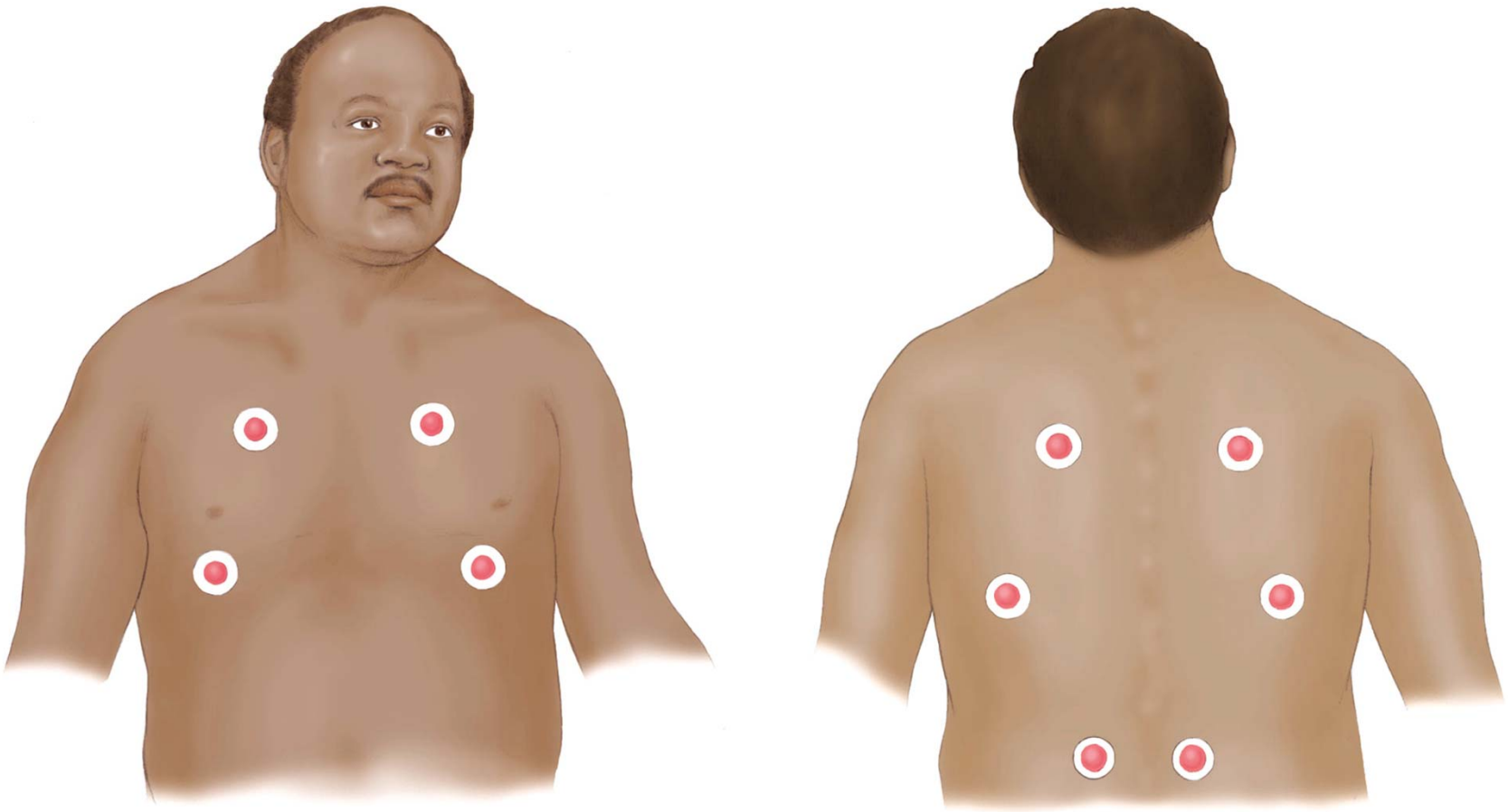

Airway Sounds

Airflow Compromise	Gas Exchange Compromise
Snoring	Crackles
Gurgling	Rhonchi
Stridor	
Wheezing	
Quiet	

Palpation

- Palpate chest wall for tenderness, symmetry, abnormal motion, crepitus, and subcutaneous emphysema.
- Assess compliance of lungs.

Noninvasive Respiratory Monitoring

Pulse oximeter

Colorimetric End-Tidal CO_2 Detector

Electronic End-Tidal CO_2 Detector -- Phillips

Capnometry - 1

- End-tidal CO2 (EtCO2) is the measurement of carbon dioxide (CO2) in the airway at the end of each breath
- Capnography provides a numeric reading (amount) and graphic display (waveform) of the EtCO2 throughout the respiratory cycle

Capnometry - 2

- Gives *immediate* feedback on respiratory status
- Pulse oximetry is delayed – a ‘dangerously long time’
- CO2, produced by cells, is transported via the vascular system and diffused into the alveoli exhaled

Capnometry - 3

- Capnography is an objective monitoring tool for patients in respiratory distress and patients undergoing procedural sedation
- It may be used to confirm, monitor and document ET tube intubation
  - **IN NYC REMAC, "NO Capnometry, NO ADVANCED AIRWAY!"**
- A nasal-oral cannula is used to assess,
- monitor and document the respiratory status of the nonintubated patient

Capnometry - **Intubated Patient**

- Verification of ET tube placement
- Monitoring and detection ET tube dislodgment
- Loss of circulatory function
- Determination of adequate CPR compressions
- Confirmation of return of spontaneous circulation

The device on a ET tube



Capnometry – **Non-Intubated Patient**

- Assessment of asthma and COPD
- Documented monitoring during procedural sedation
- Detection of apnea or inadequate breathing
- Measurement of hypoventilation
- Evaluation of hyperventilation

Figure 8-7 Electronic end-tidal CO_2 detector on a patient. *(© Scott Metcalfe)*

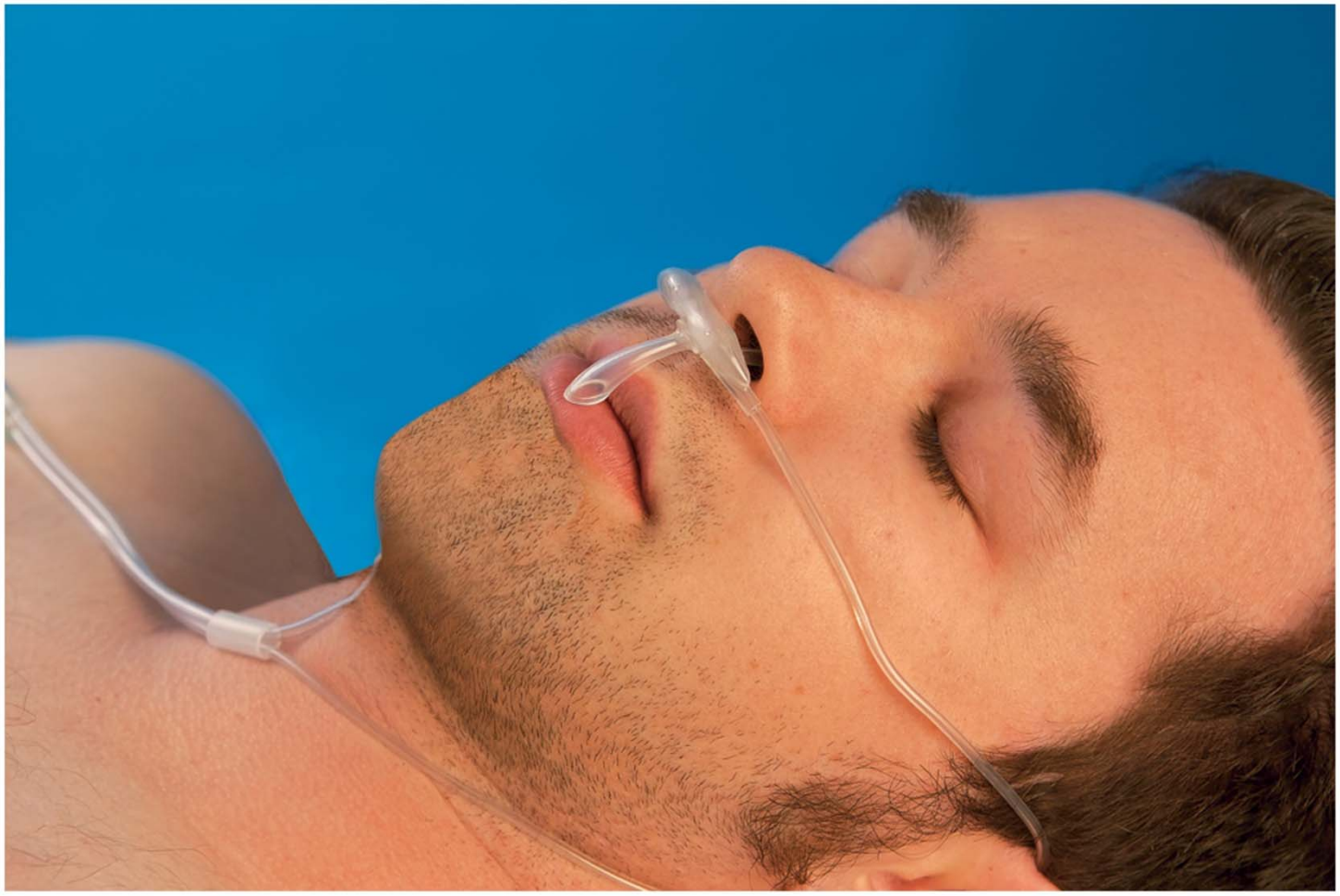

Figure 8-8 Most quantitative electronic $ETCO_2$ detectors can provide a digital waveform (capnogram) that reflects the entire respiratory cycle. *(© Scott Metcalfe)*

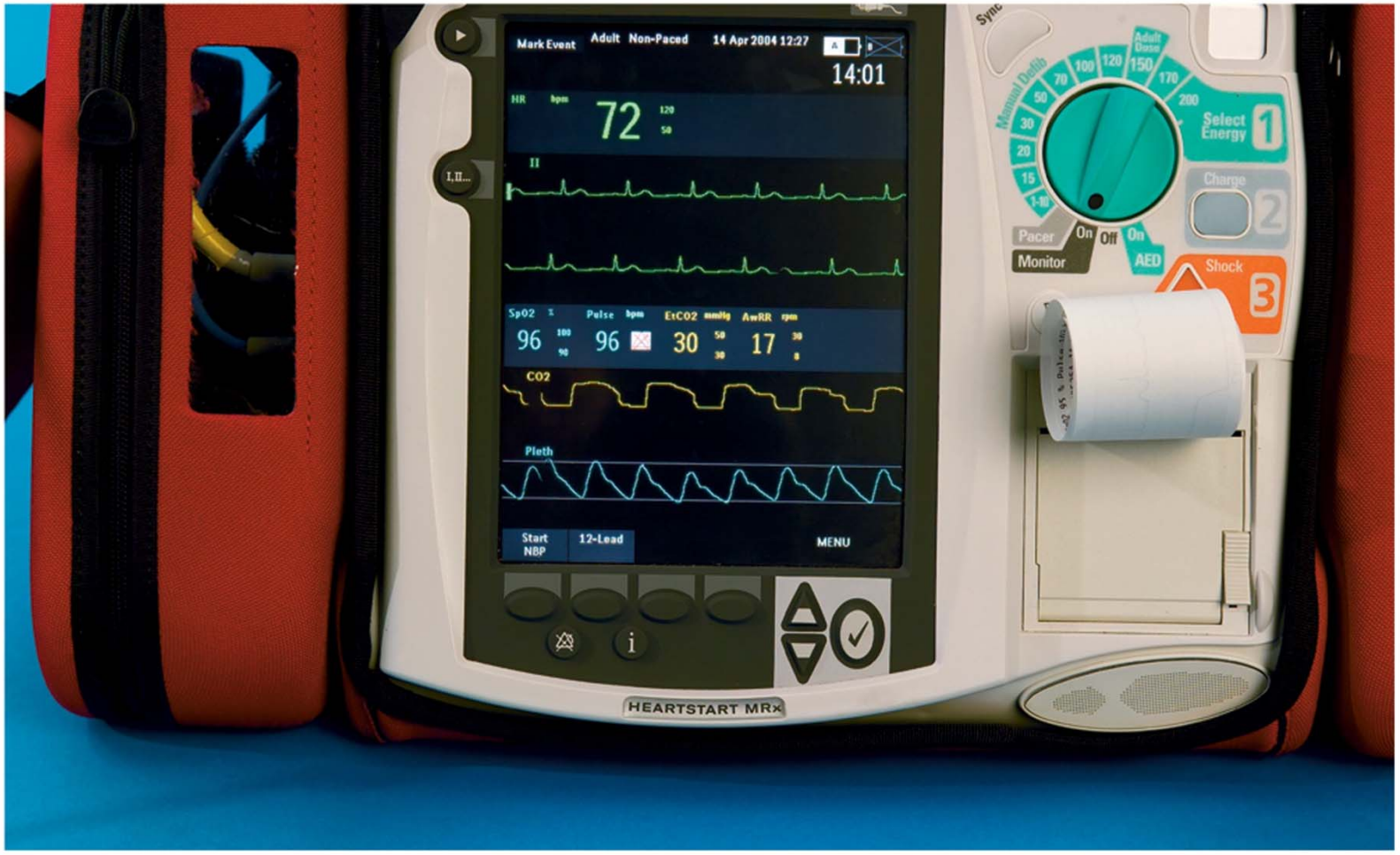

Figure 8-9 Normal capnogram. AB = *Phase I:* late inspiration, early expiration (no CO_2). BC = *Phase II:* appearance of CO_2 in exhaled gas. CD = *Phase III:* plateau (constant CO_2). D = highest point ($ETCO_2$). DE = *Phase IV:* rapid descent during inspiration. EA = respiratory pause.

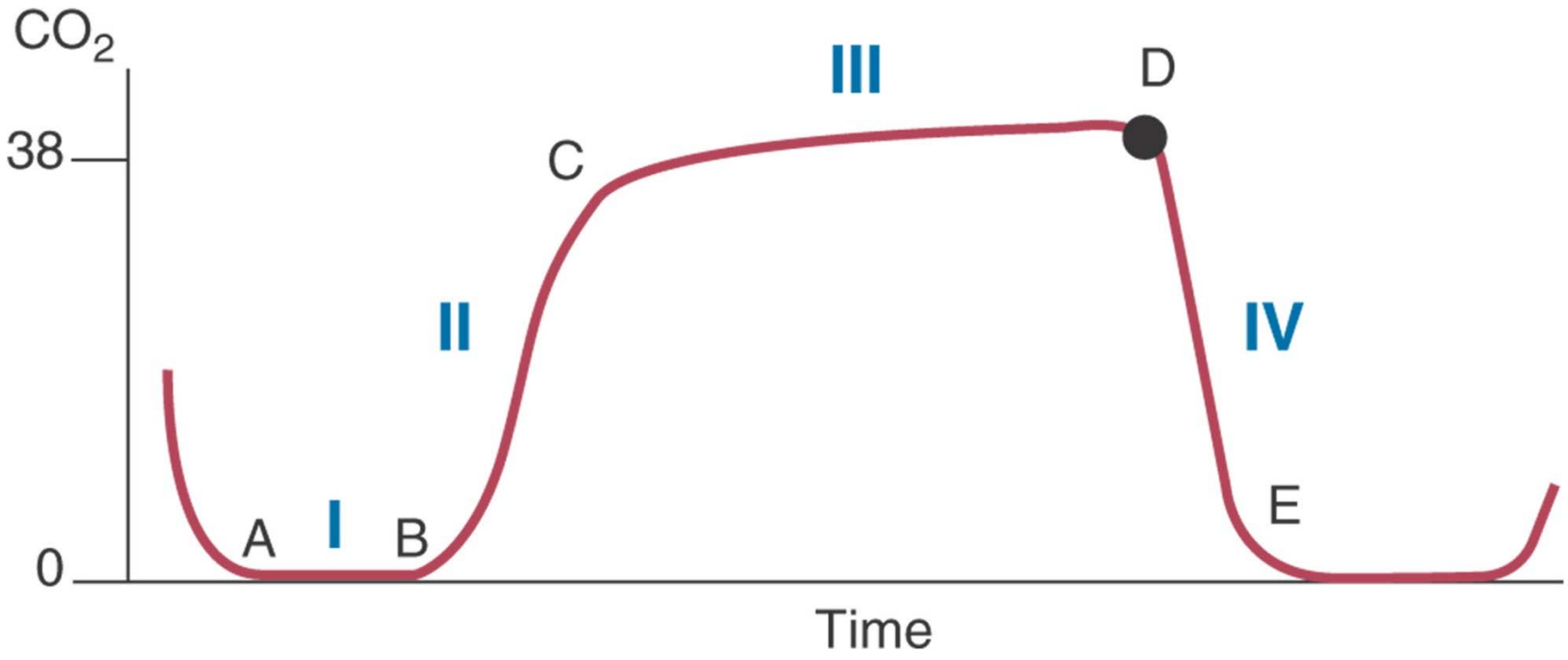

Respiratory Phases

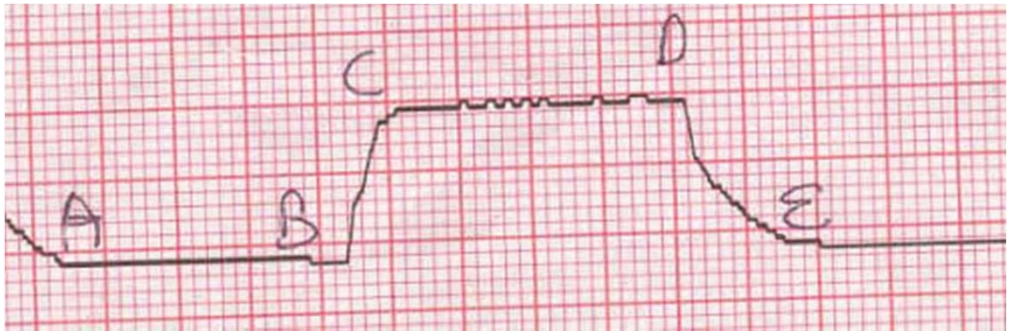

Capnogram Component	**Respiratory Phase**
A-B	Respiratory Baseline
B-C	Expiratory “upslope”
C-D	Expiratory “plateau”
D	**End Tidal CO2**
D-E	Inspiratory downstroke

SPO2 vs. Capnography

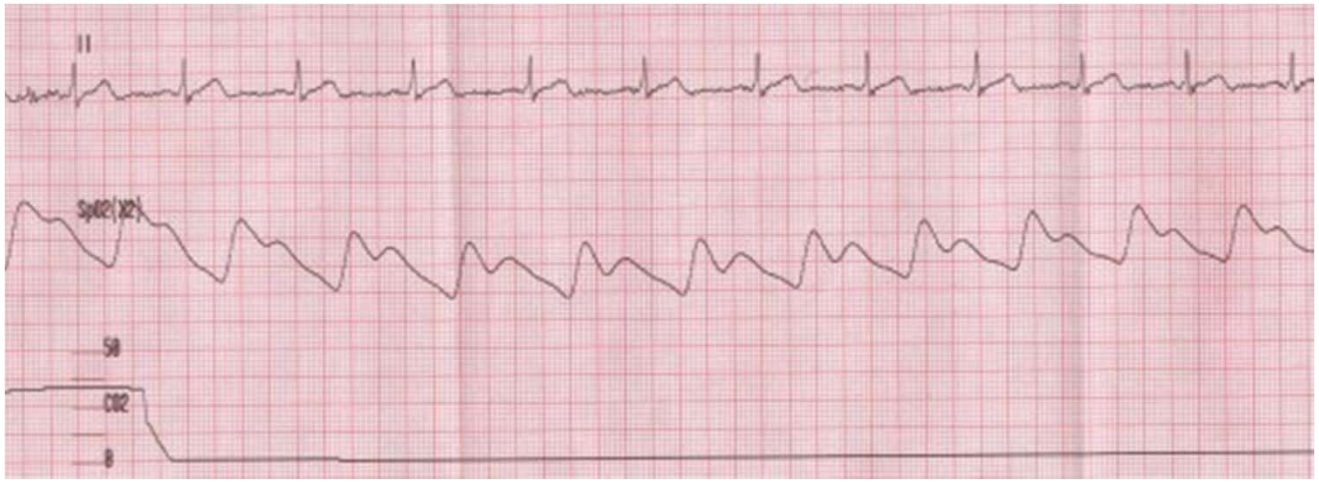

Normal Capnography Waves



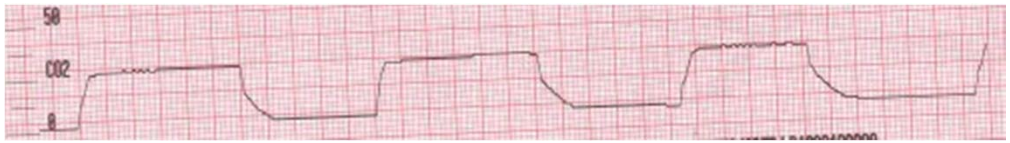

Successful Intubation

Woops – it’s NOT in the trachea!

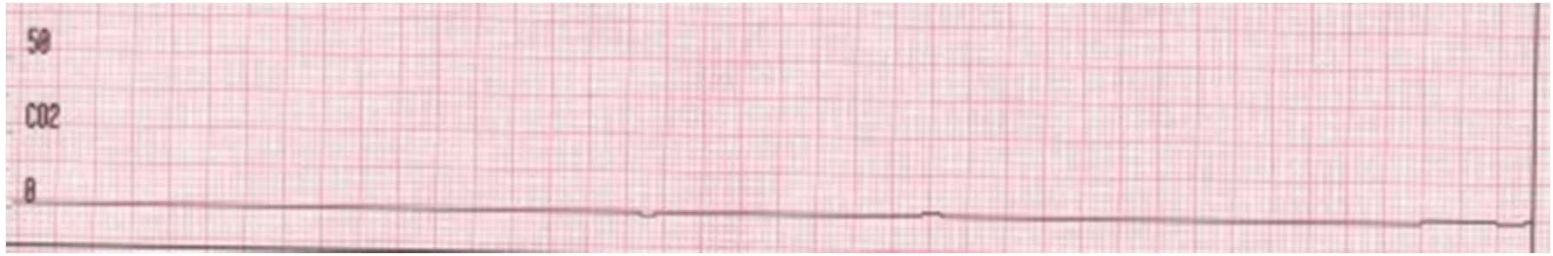

Hyperventilation

Hypoventilation

In Cardiac Arrest

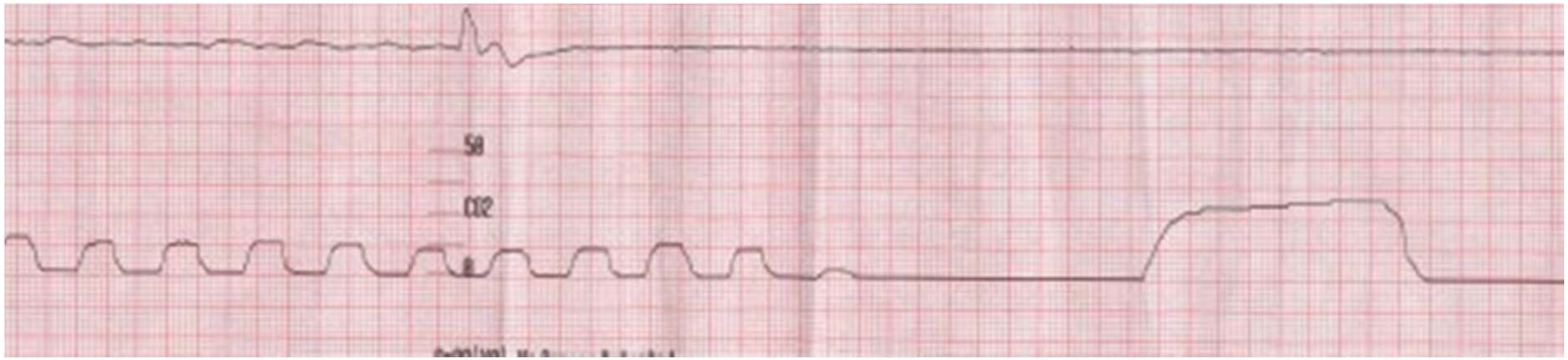

Asthmatic/COPD– “Shark Fin”

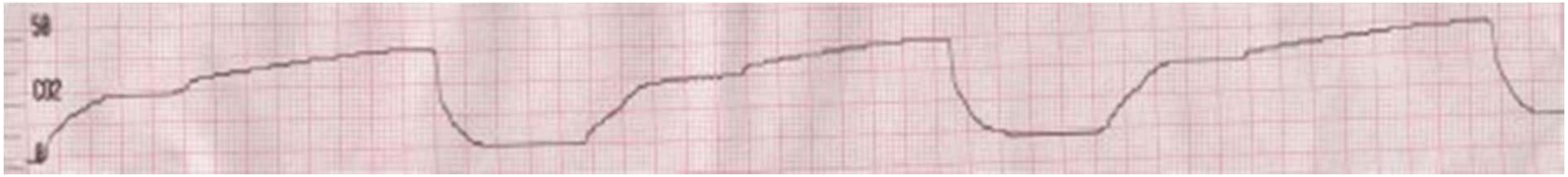

Asthmatic Being Treated

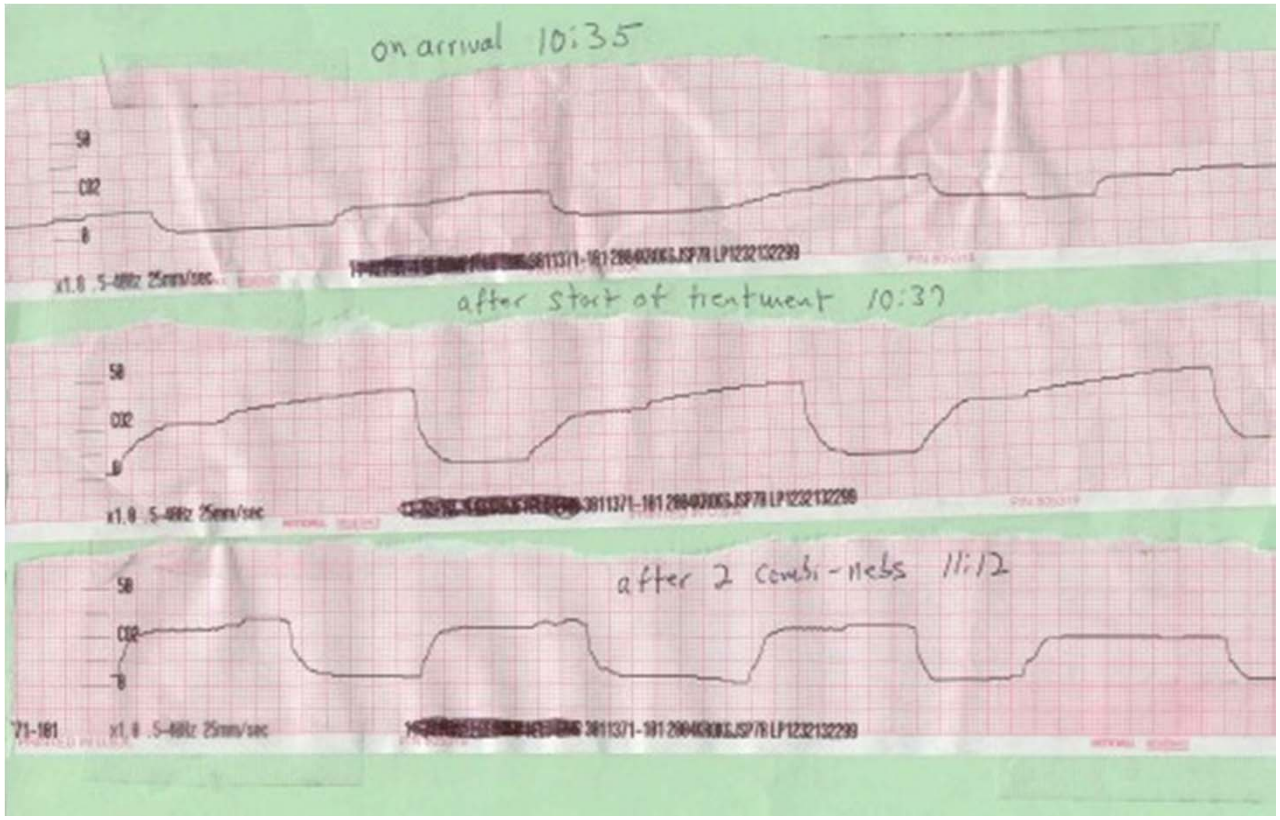

Manual Airway Maneuvers

Head-tilt/chin-lift

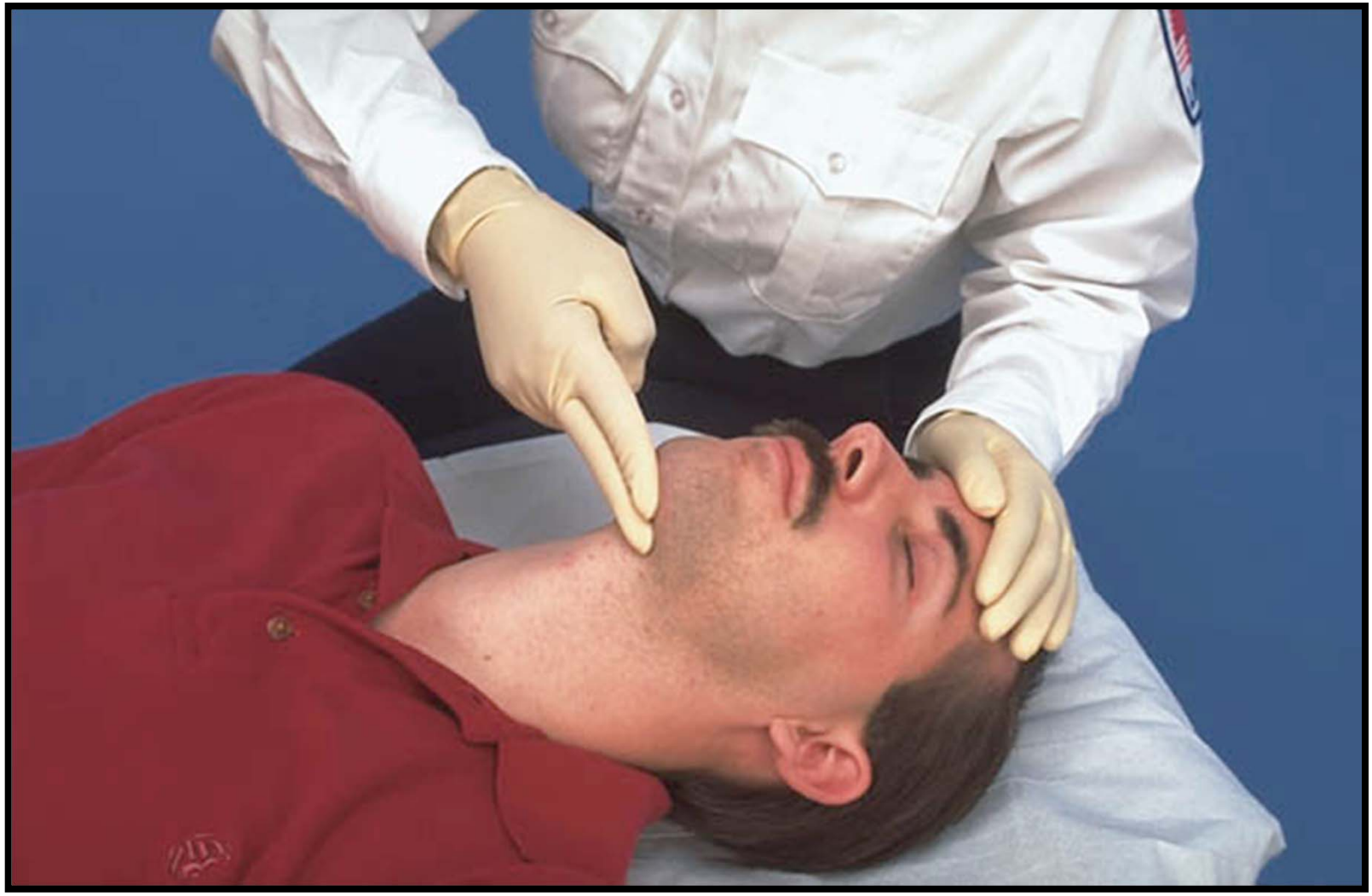

Modified jaw-thrust in trauma

Jaw-thrust maneuver

Jaw-lift maneuver

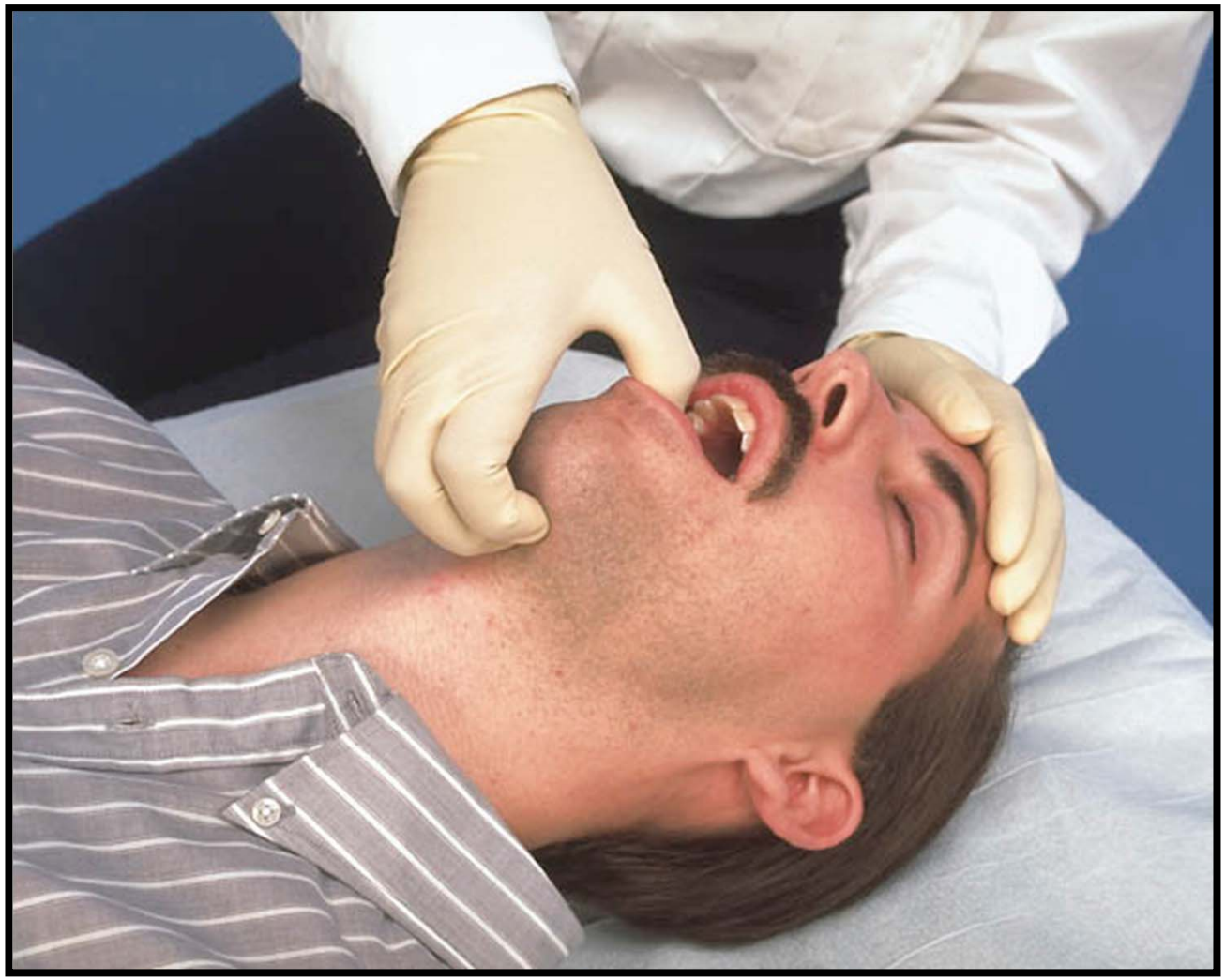

Airway before applying Sellick's

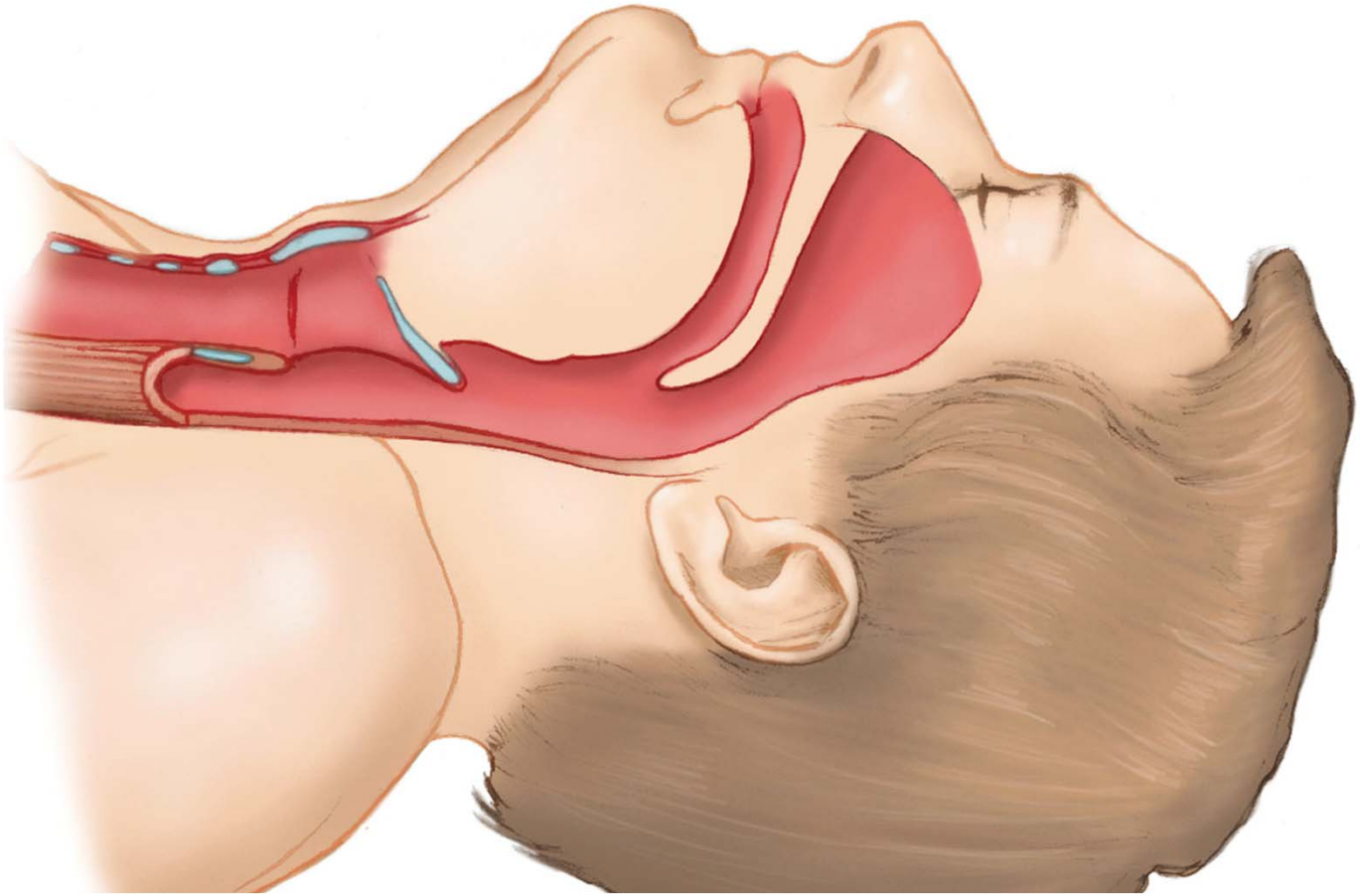

Sellick's maneuver (cricoid pressure)

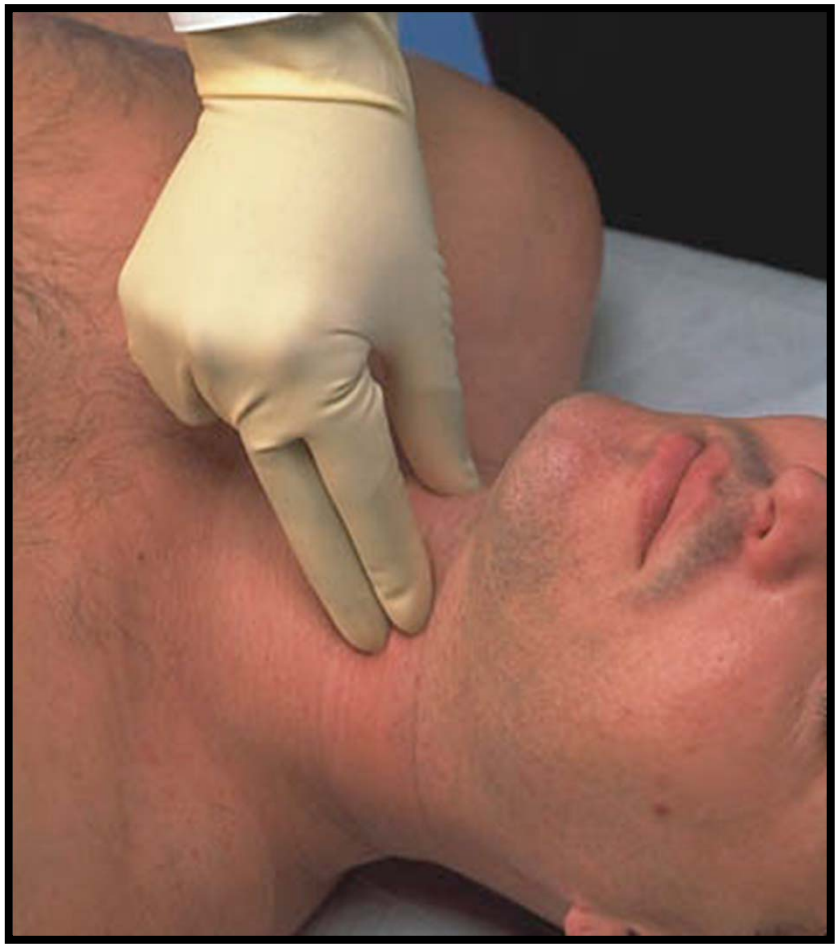

Airway with Sellick's applied (note compression on the esophagus)

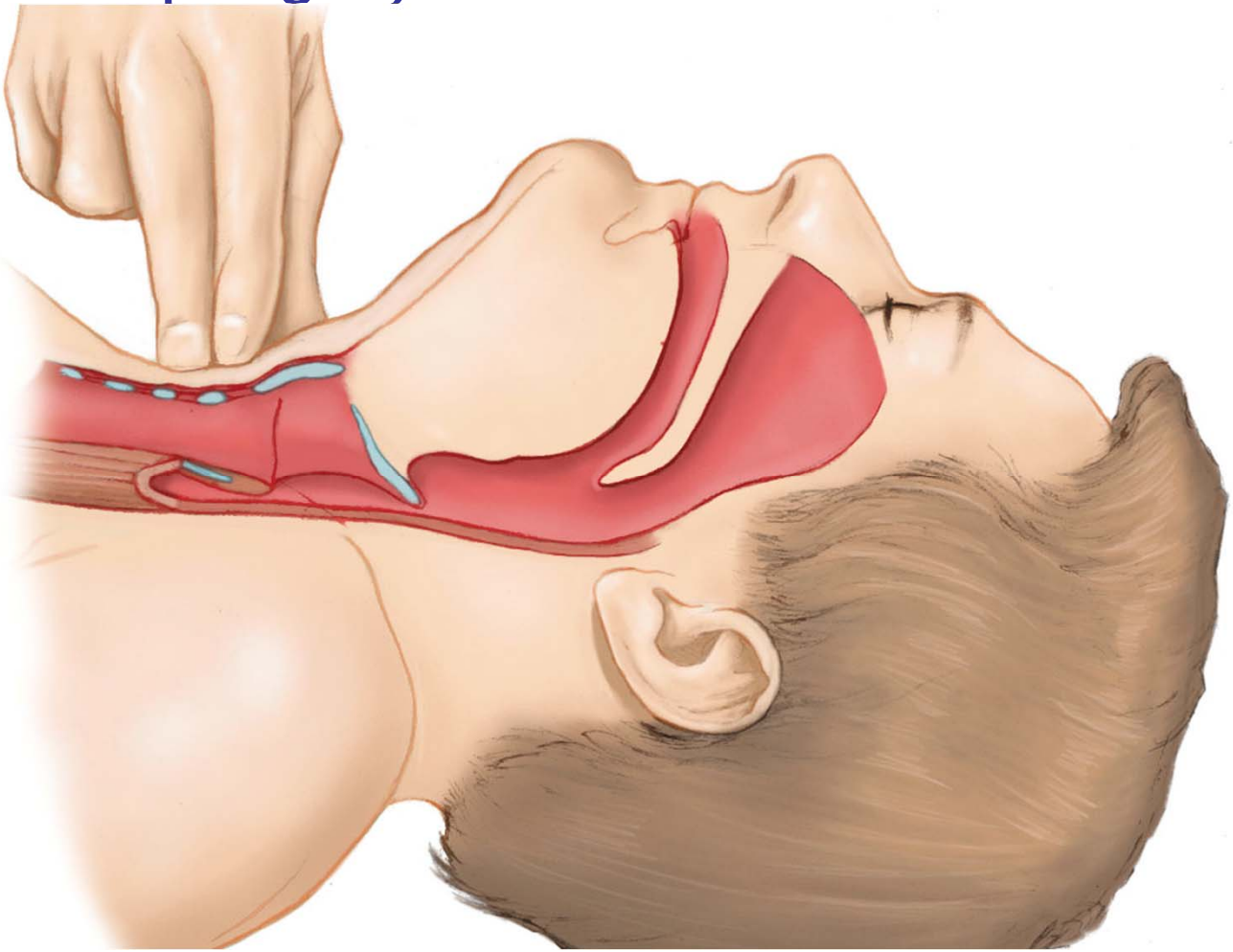

Sellick's Maneuver – Cricoid pressure

No longer recommended per 2010
AHA Standards

Basic Mechanical Airways

Nasopharyngeal airway

Nasopharyngeal airway, inserted

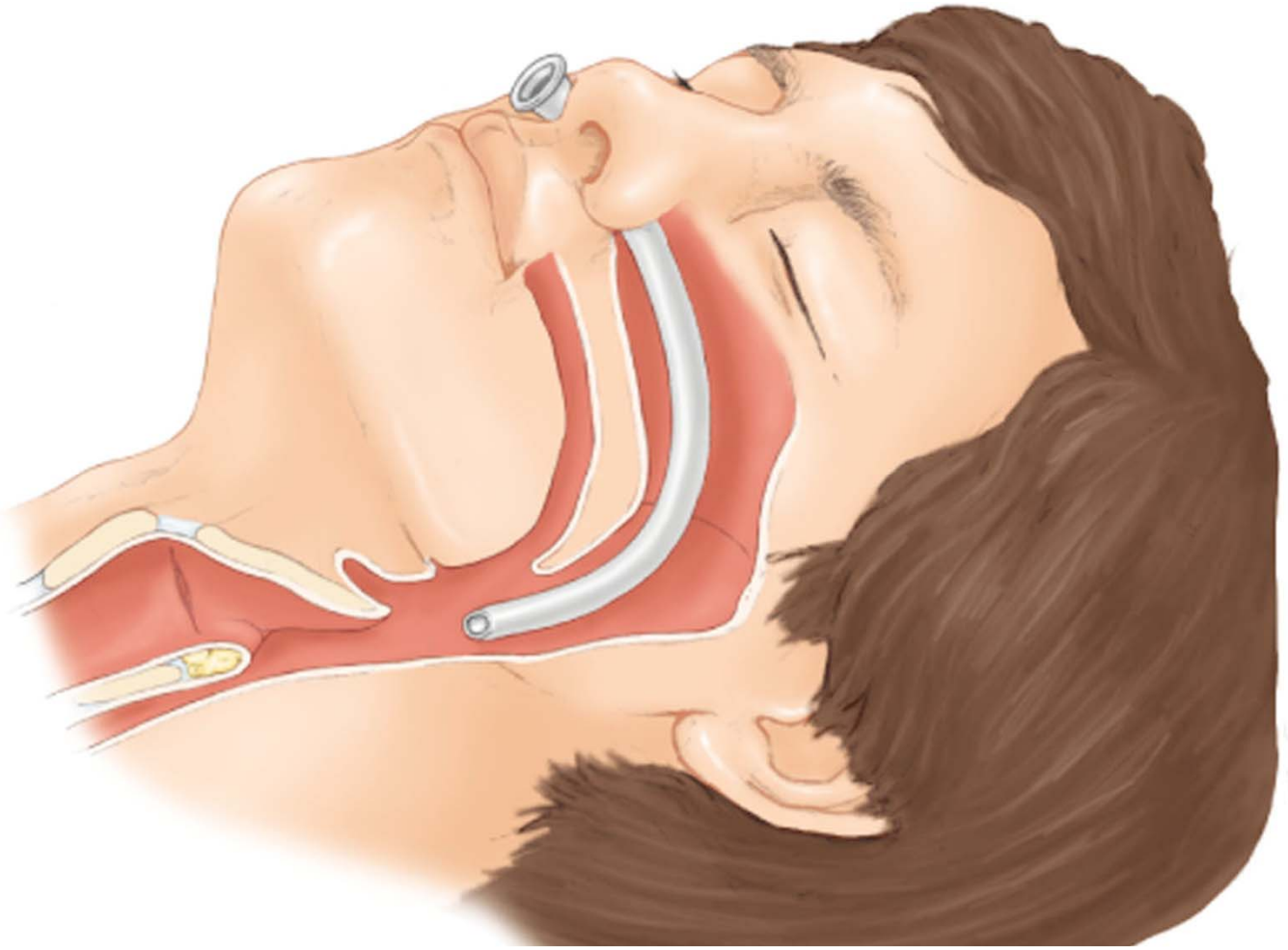

Insert oropharyngeal airway with tip facing palate.

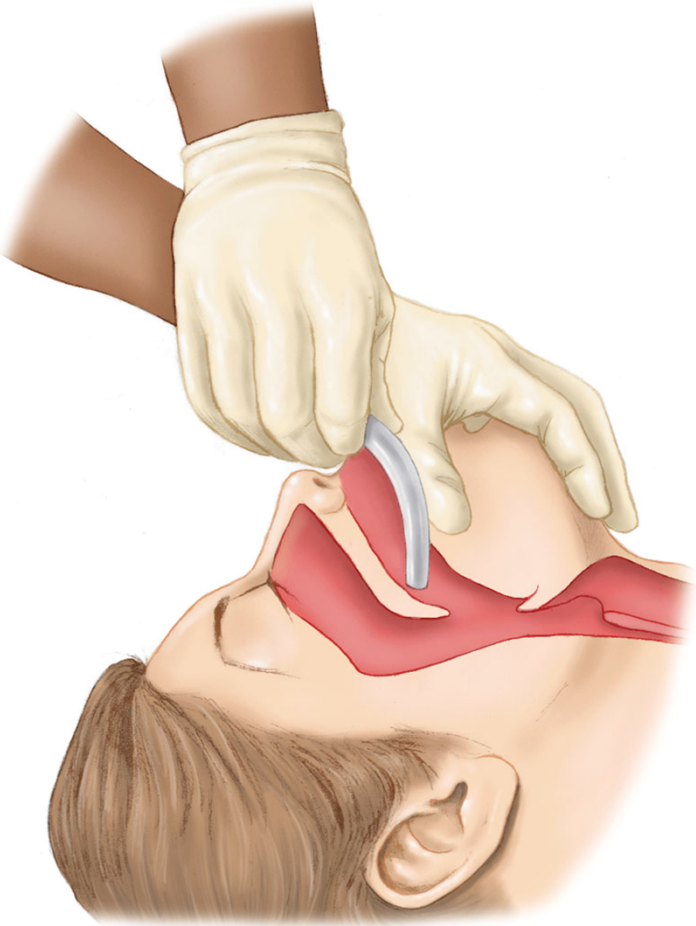

Rotate airway 180° into position.

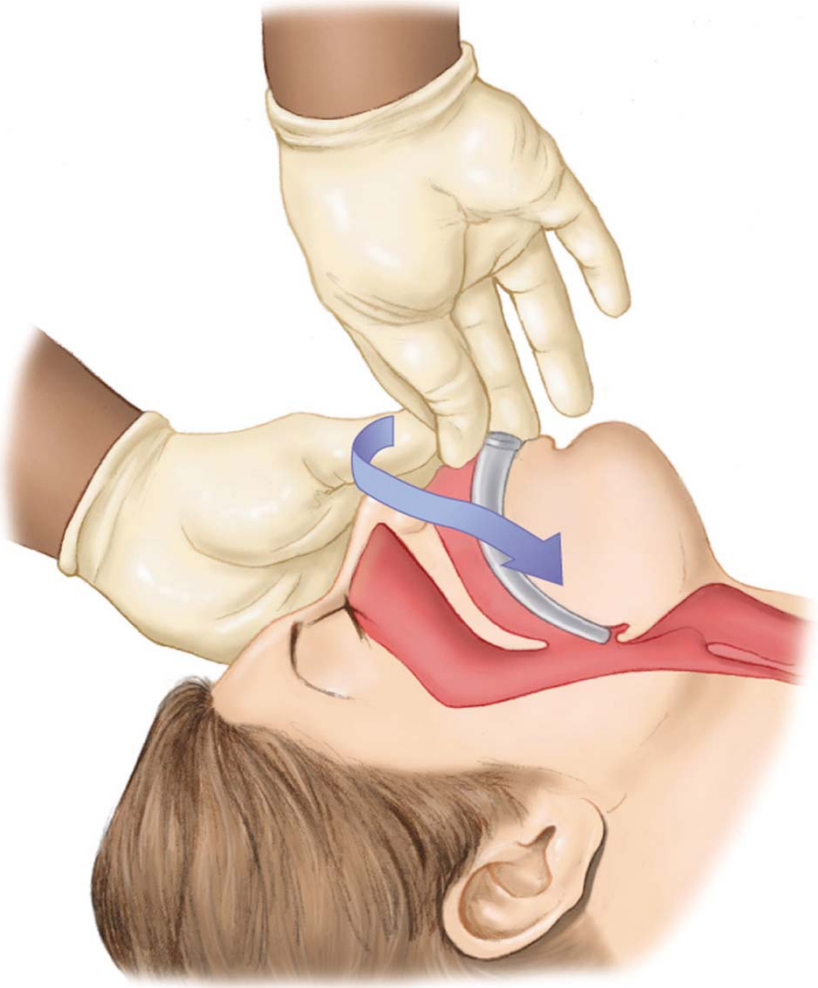

Improper placement of oropharyngeal airway

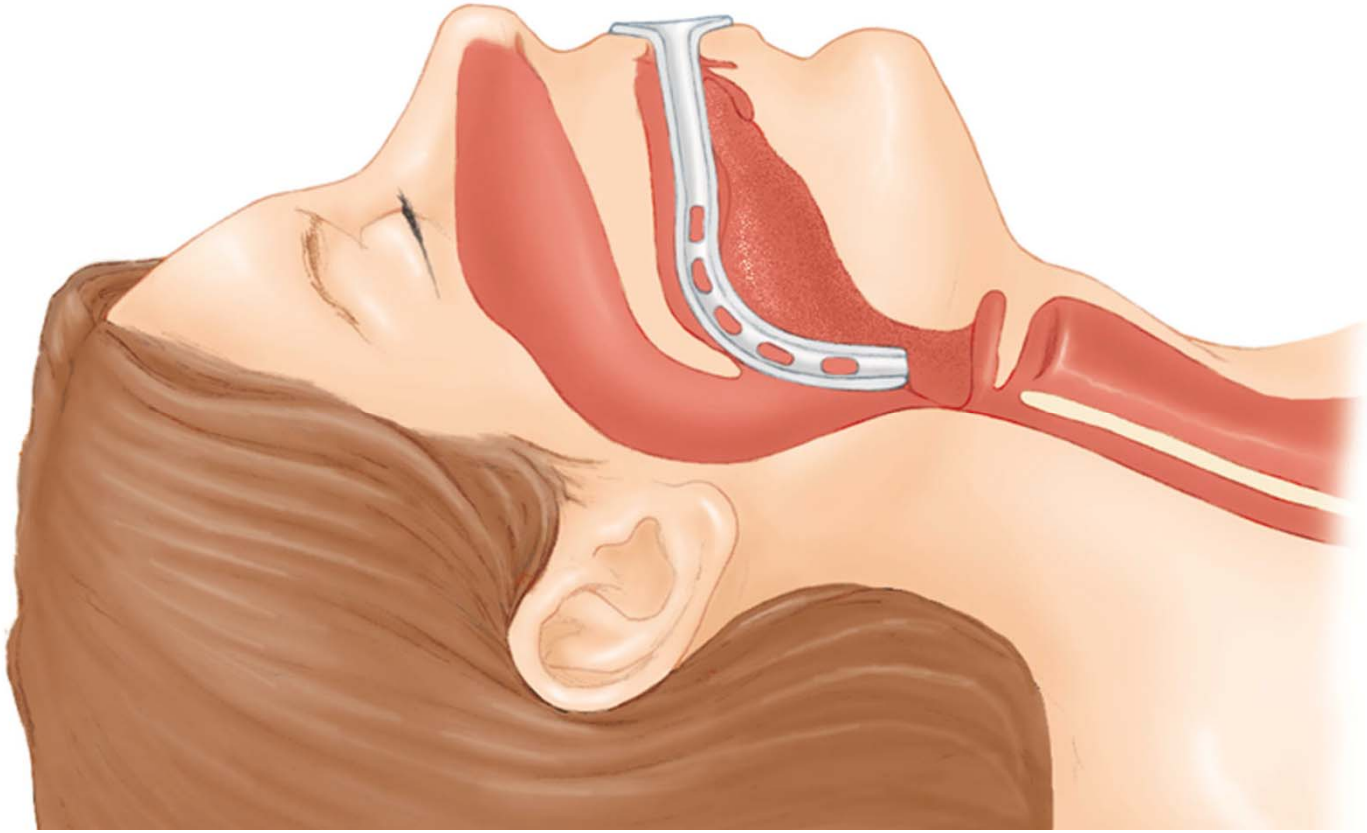

Advanced Airway Management

Endotracheal intubation
is clearly the preferred method
of advanced airway management in prehospital emergency care.

Endotracheal Intubation

Engaging laryngoscope blade and handle

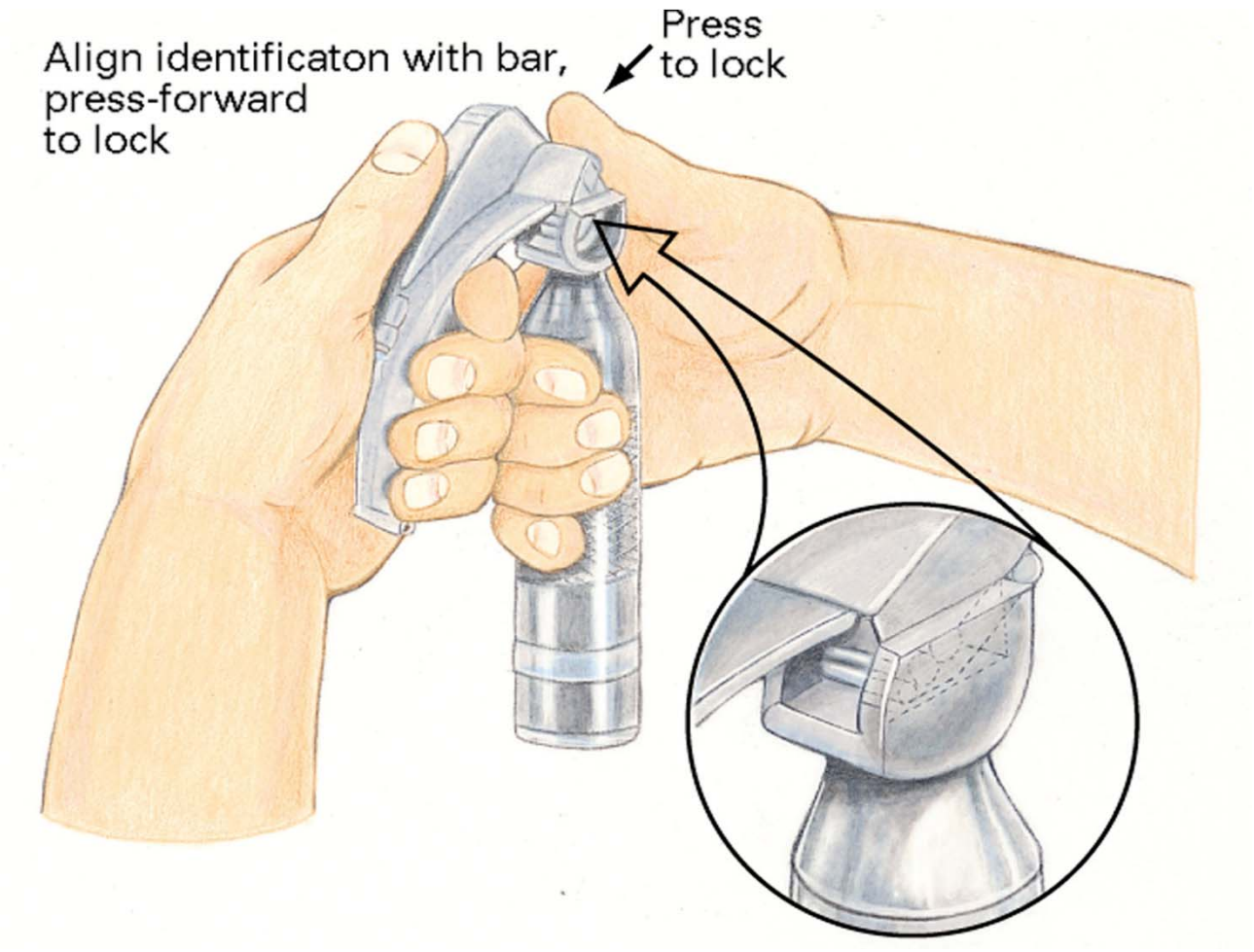

Activating laryngoscope light source

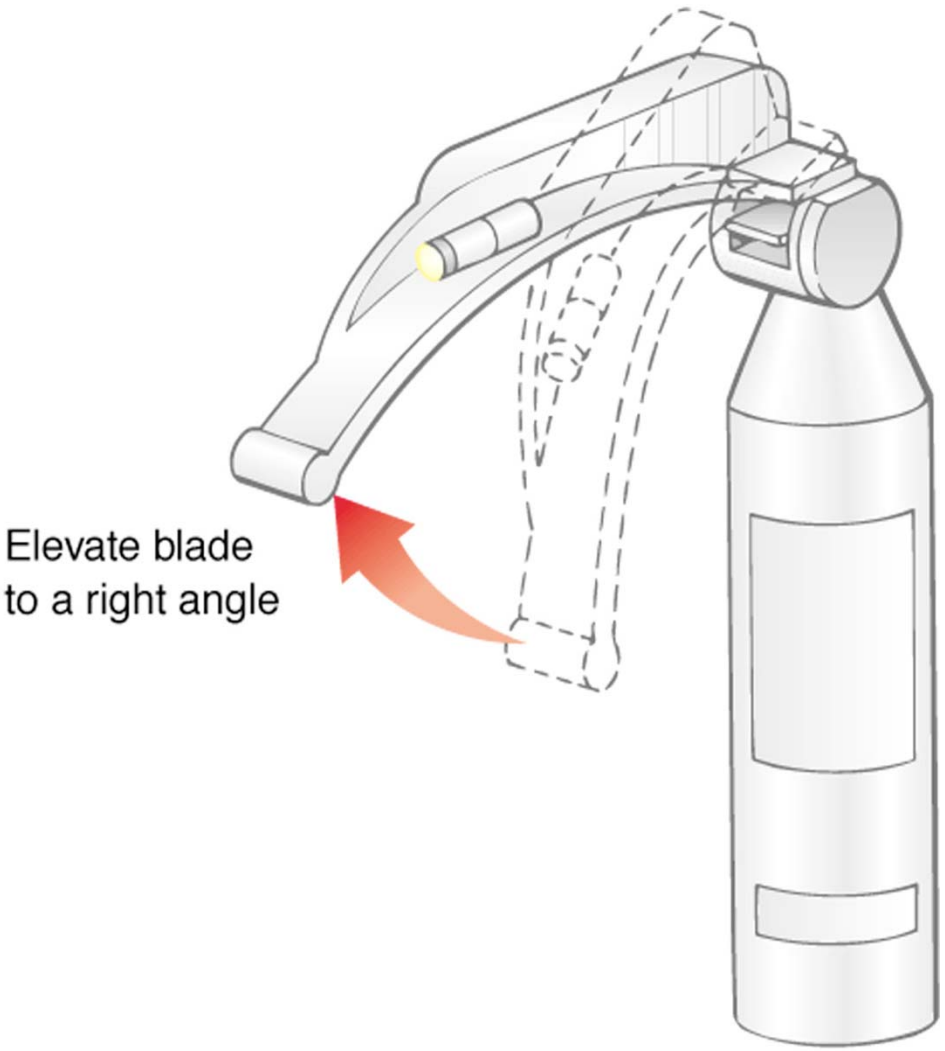

Laryngoscope blades

Placement of Macintosh blade into vallecula

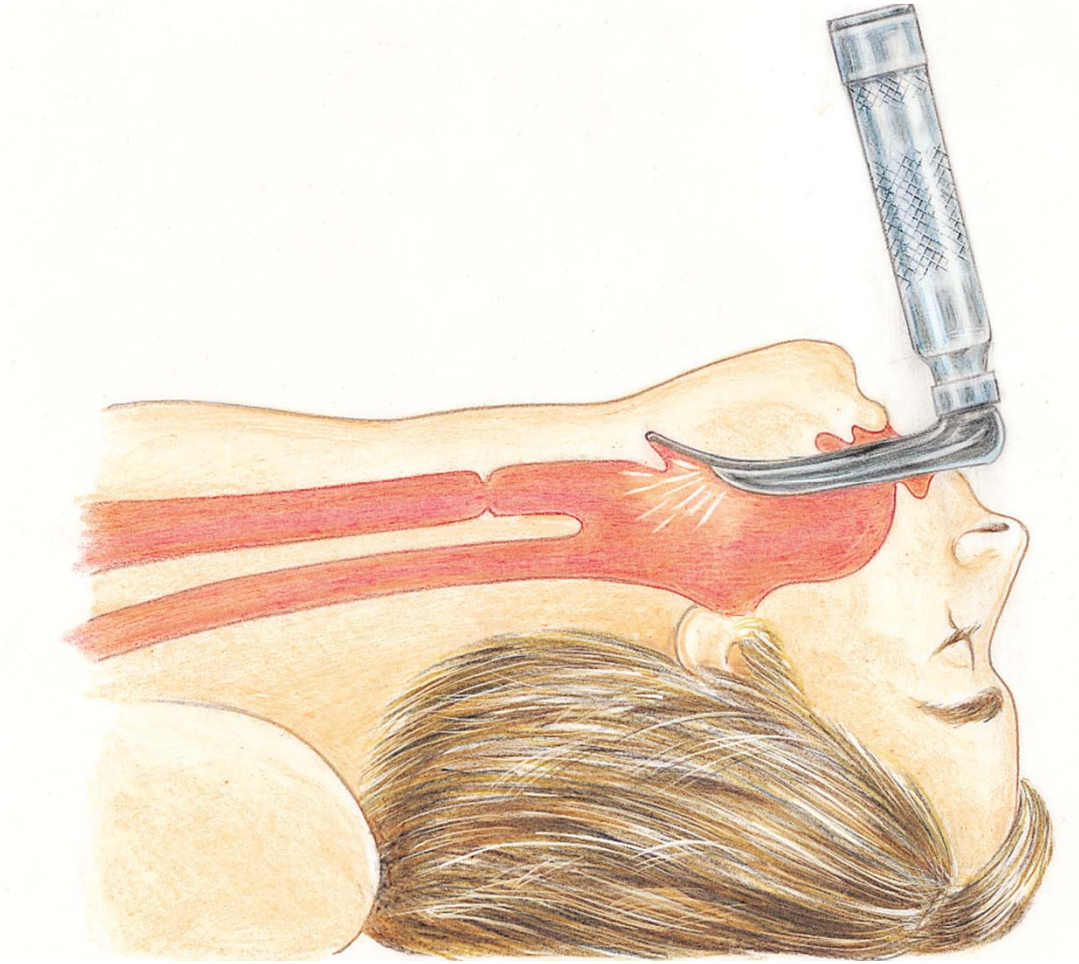

Placement of Miller blade under epiglottis

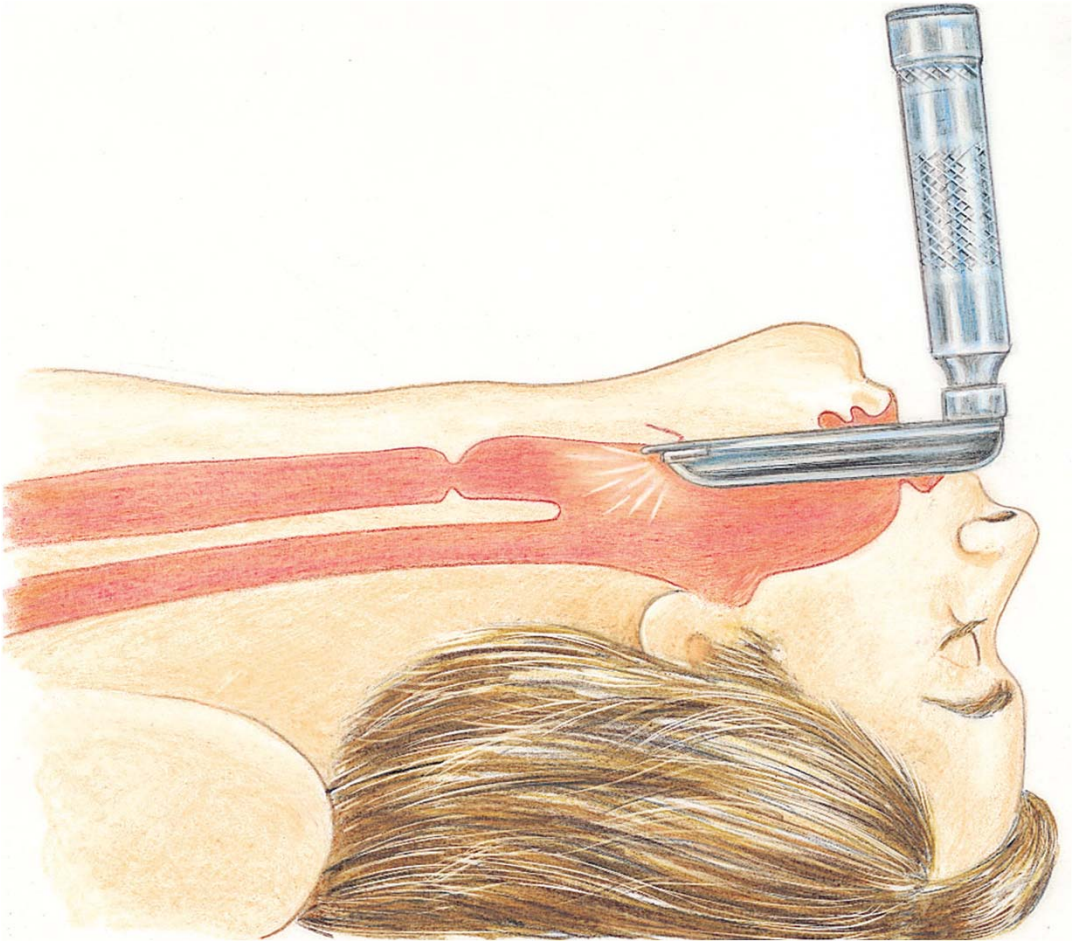

ETT and syringe

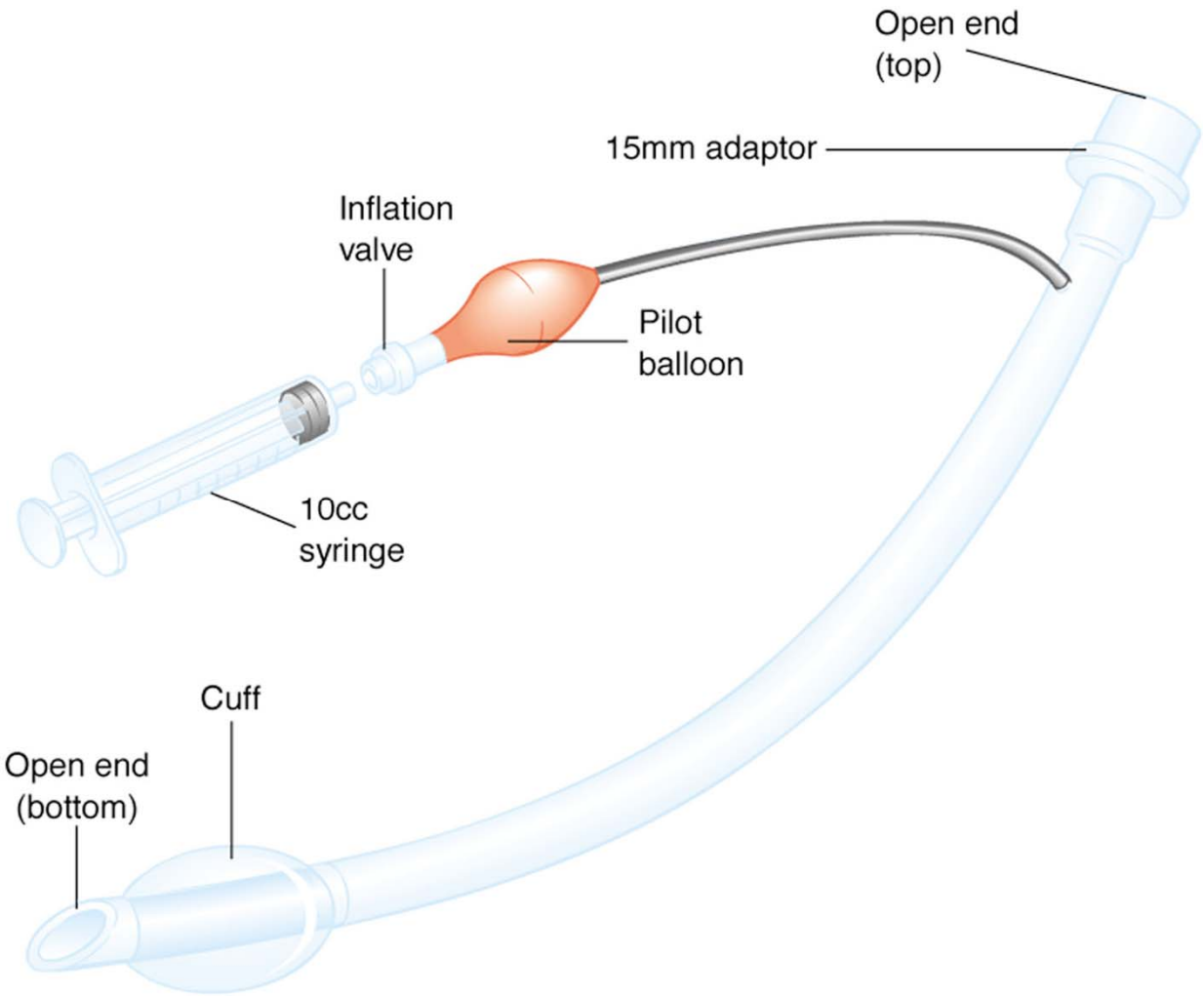

Endotrol ETT

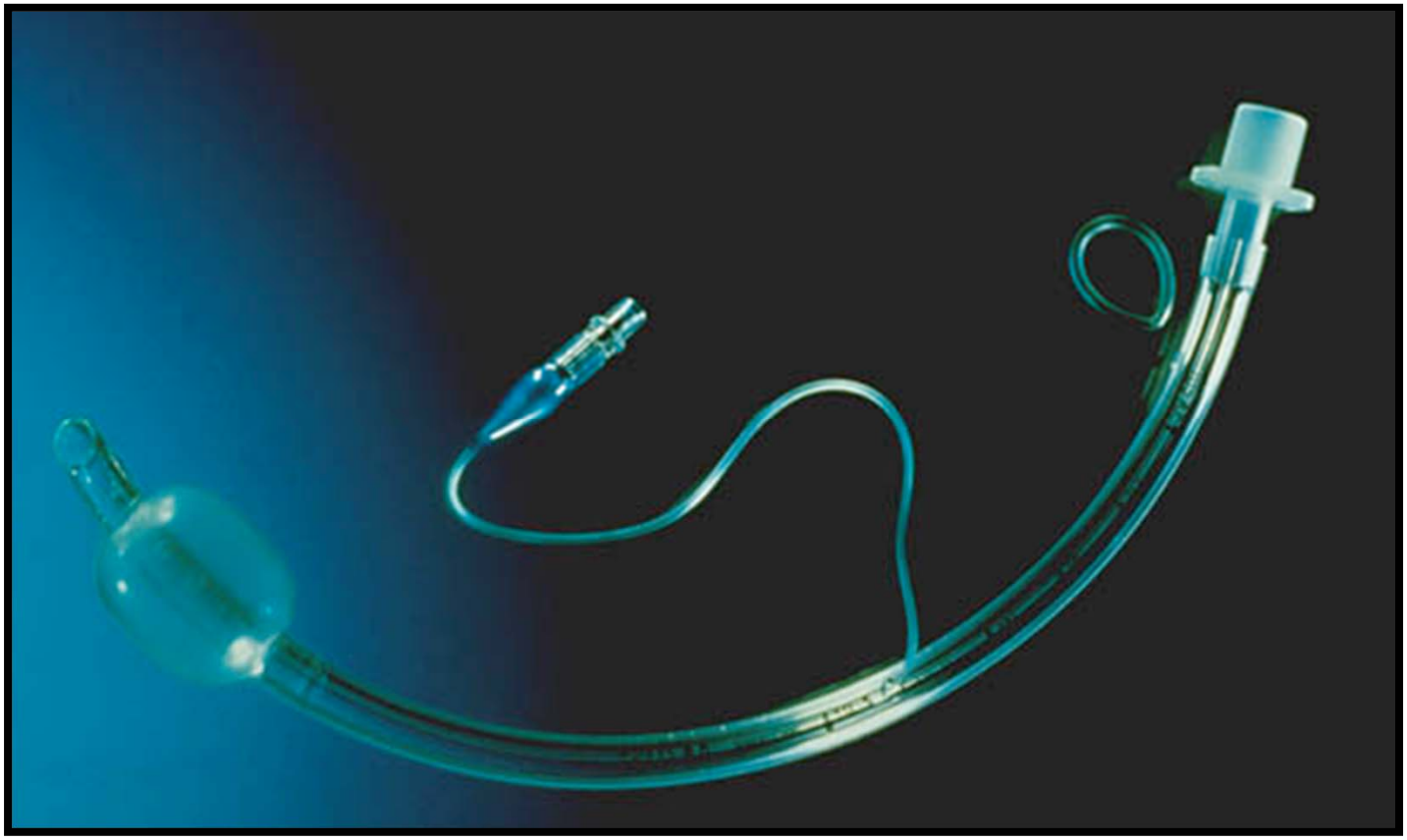

ETT, stylet, and syringe, unassembled

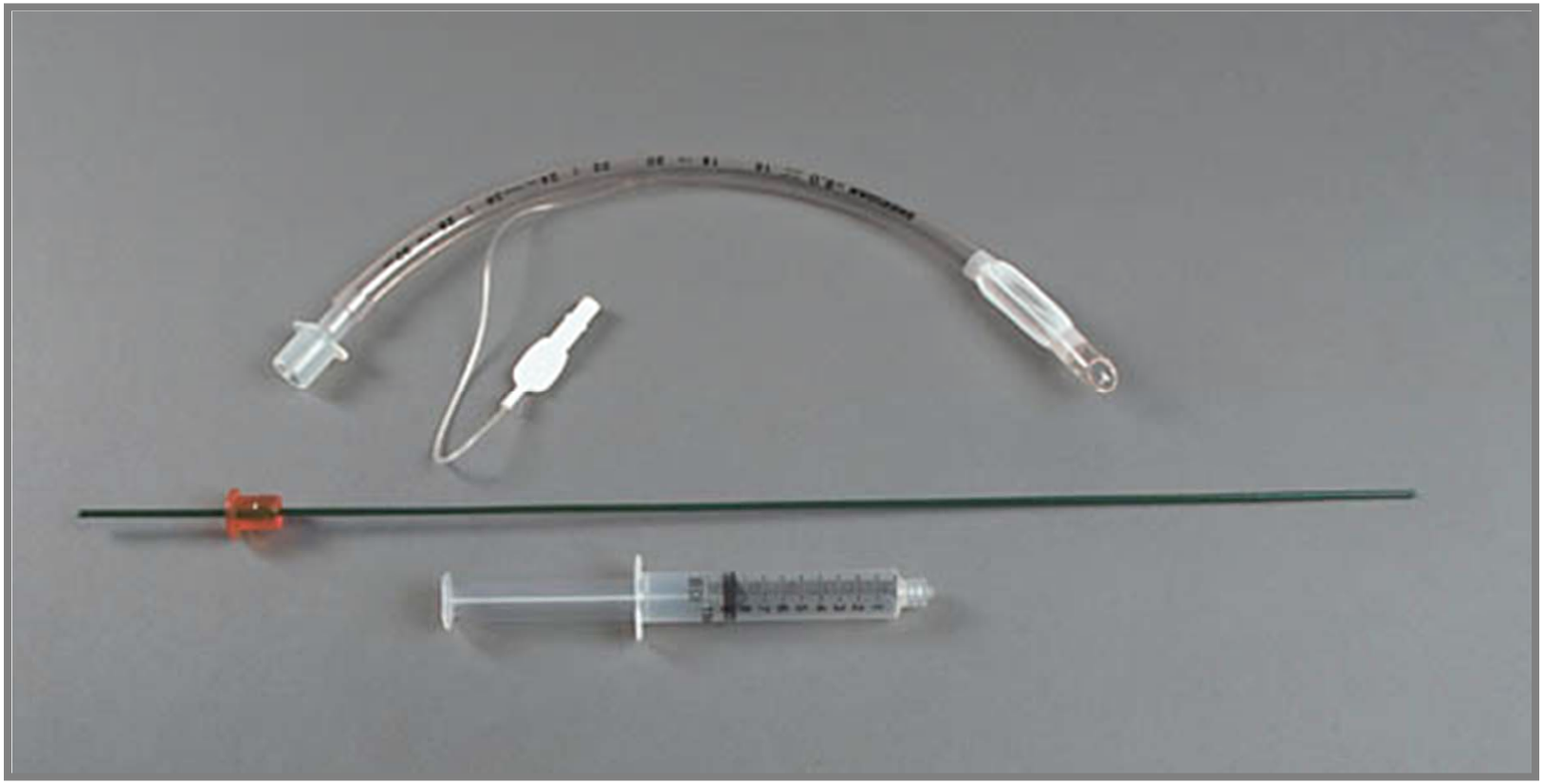

ETT, stylet, and syringe, assembled for intubation

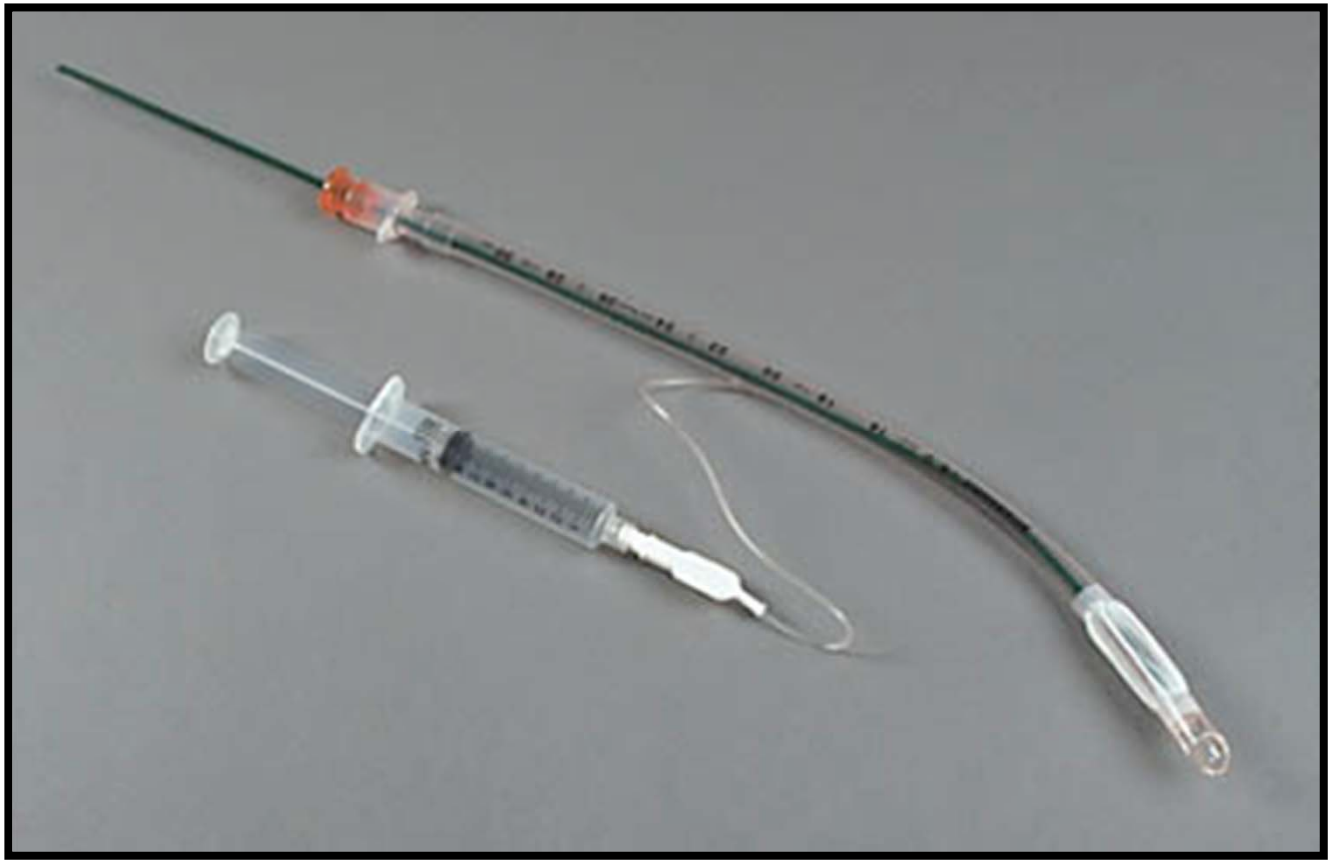

Endotracheal Intubation Indicators

- Respiratory or cardiac arrest
- Unconsciousness
- Risk of aspiration
- Obstruction due to foreign bodies, trauma, burns, or anaphylaxis
  - **Protect airway *BEFORE* it is swollen!**
- Respiratory extremis due to disease
- Pneumothorax, hemothorax, hemopneumothorax with respiratory difficulty

Advantages of Endotracheal Intubation

- Isolates trachea and permits complete control of airway
- Impedes gastric distention
- Eliminates need to maintain a mask seal
- Offers direct route for suctioning
- Permits administration of some medications
  - No longer allowed in NYC REMAC for adults
  - Pediatric scenarios exist still allowing it, but…
    - **We now have better means – "IO"**

Disadvantages of Endotracheal Intubation

- Requires considerable training and experience and practice and practice...
  - **A HUGE Problem!**
- Requires specialized equipment
- Requires direct visualization of vocal cords
- Bypasses upper airway's functions of warming, filtering, and humidifying the inhaled air

Complications of Endotracheal Intubation

- Equipment malfunction
- Teeth breakage and soft tissue lacerations
- Hypoxia
- Esophageal intubation
- Endobronchial intubation
- Tension pneumothorax

Personal protective equipment



Hyperventilate patient.

Prepare equipment.

Apply Sellick's maneuver
and insert laryngoscope.

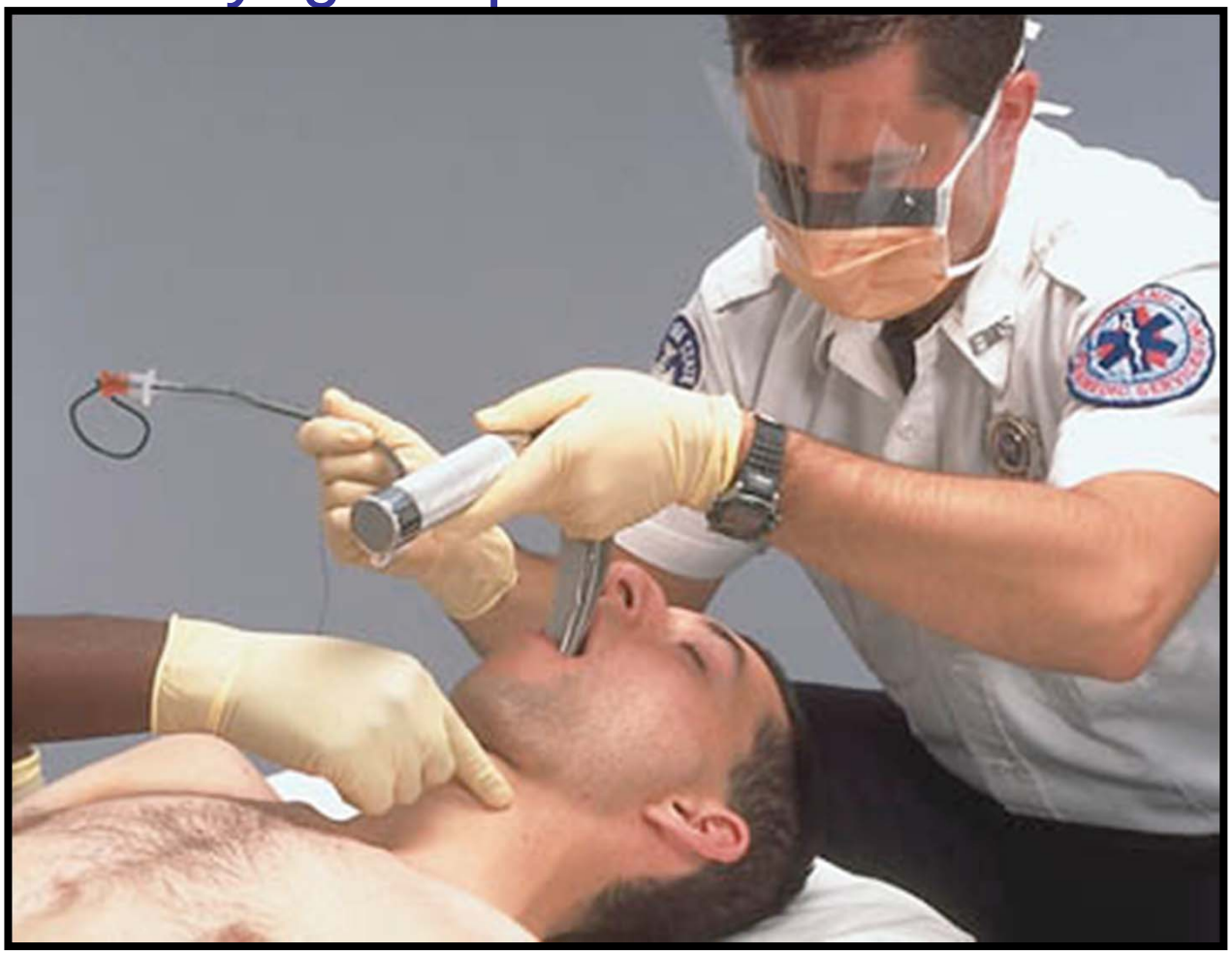

Visualize larynx and insert the ETT.

Glottis visualized
through laryngoscopy

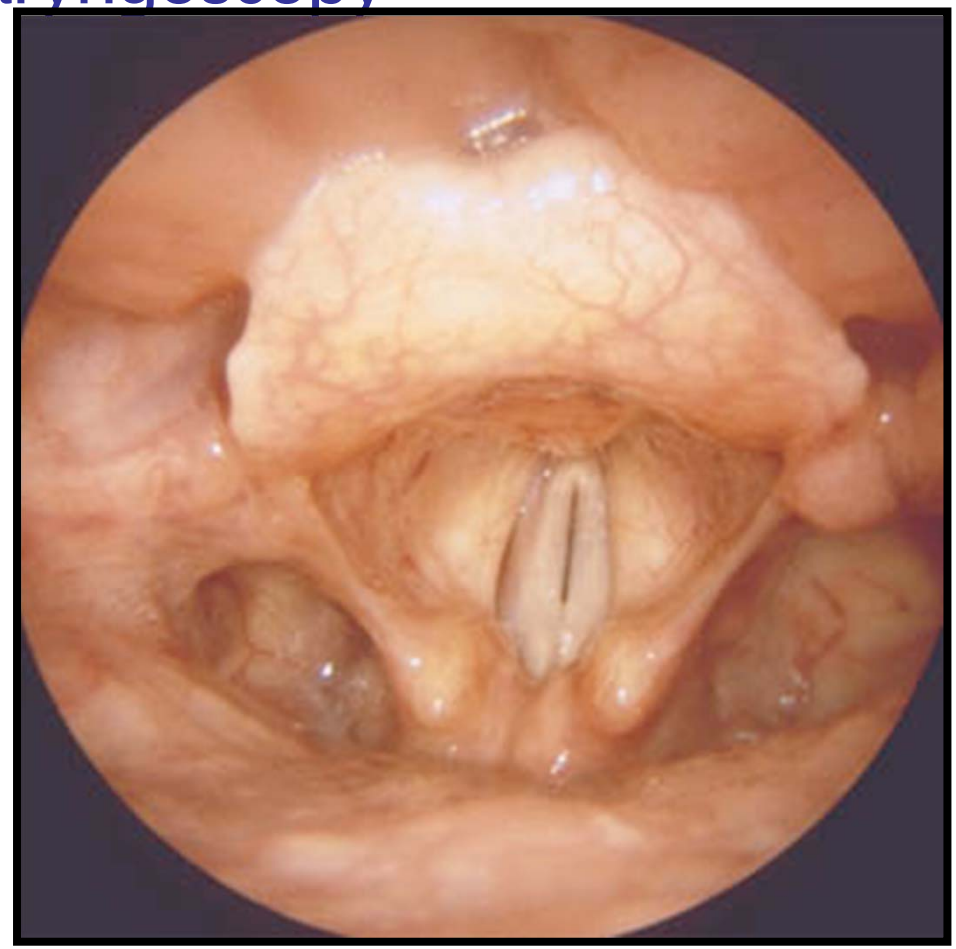

Inflate cuff, ventilate,
and auscultate

Confirm placement with an $ETCO_2$ detector.

Esophageal detector device, bulb style

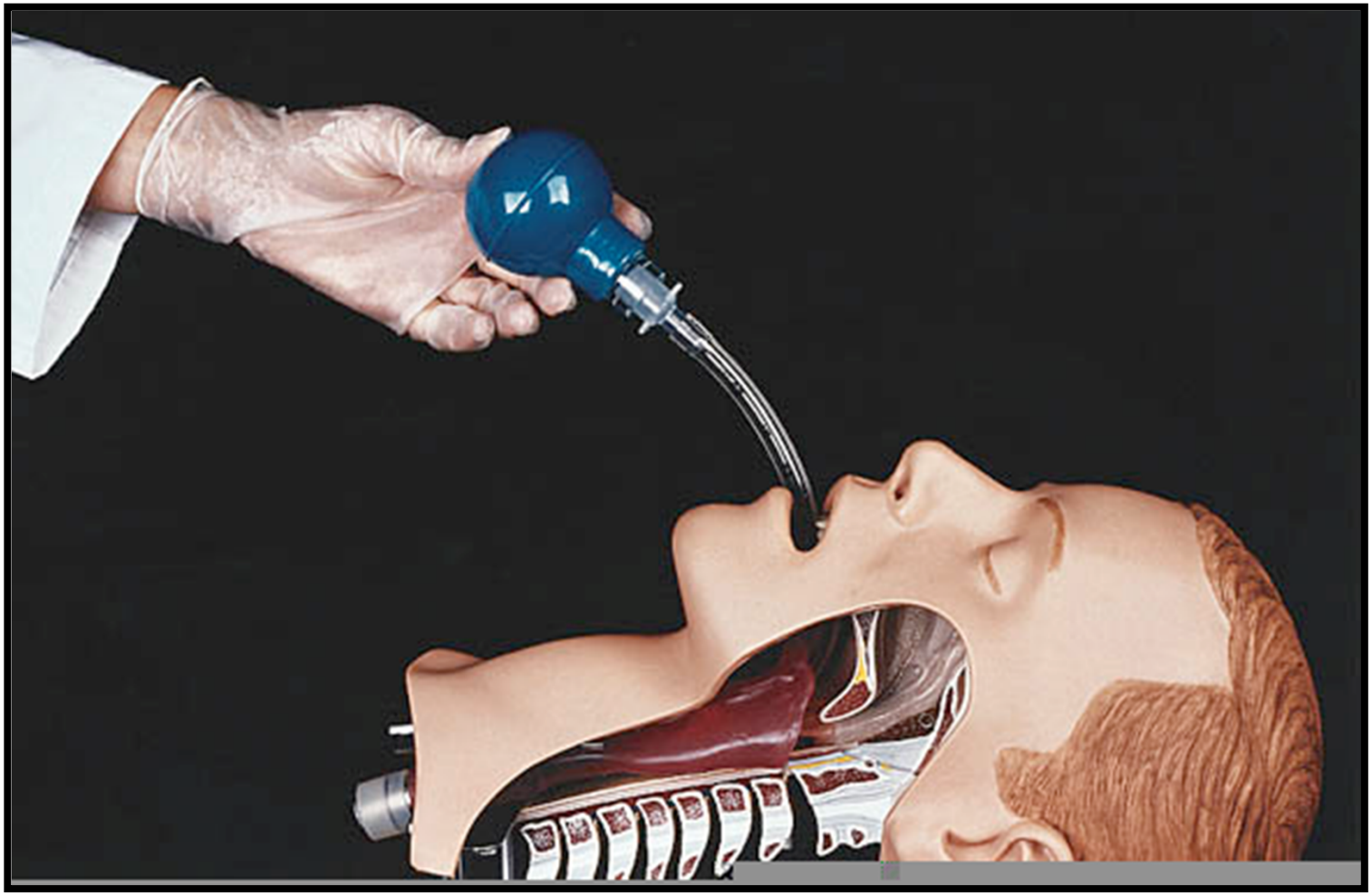

If the bulb does not refill,
the tube is improperly placed.

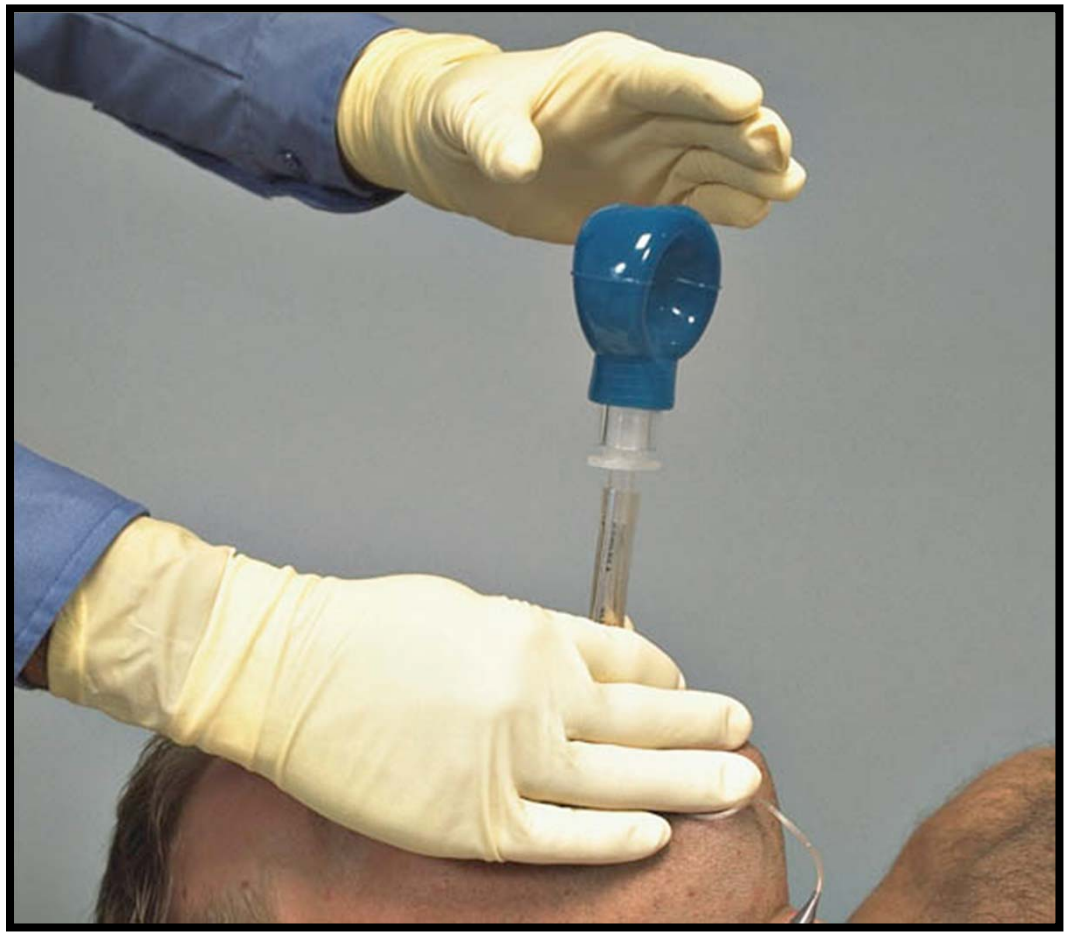

Attach device to endotracheal tube and squeeze the detector.

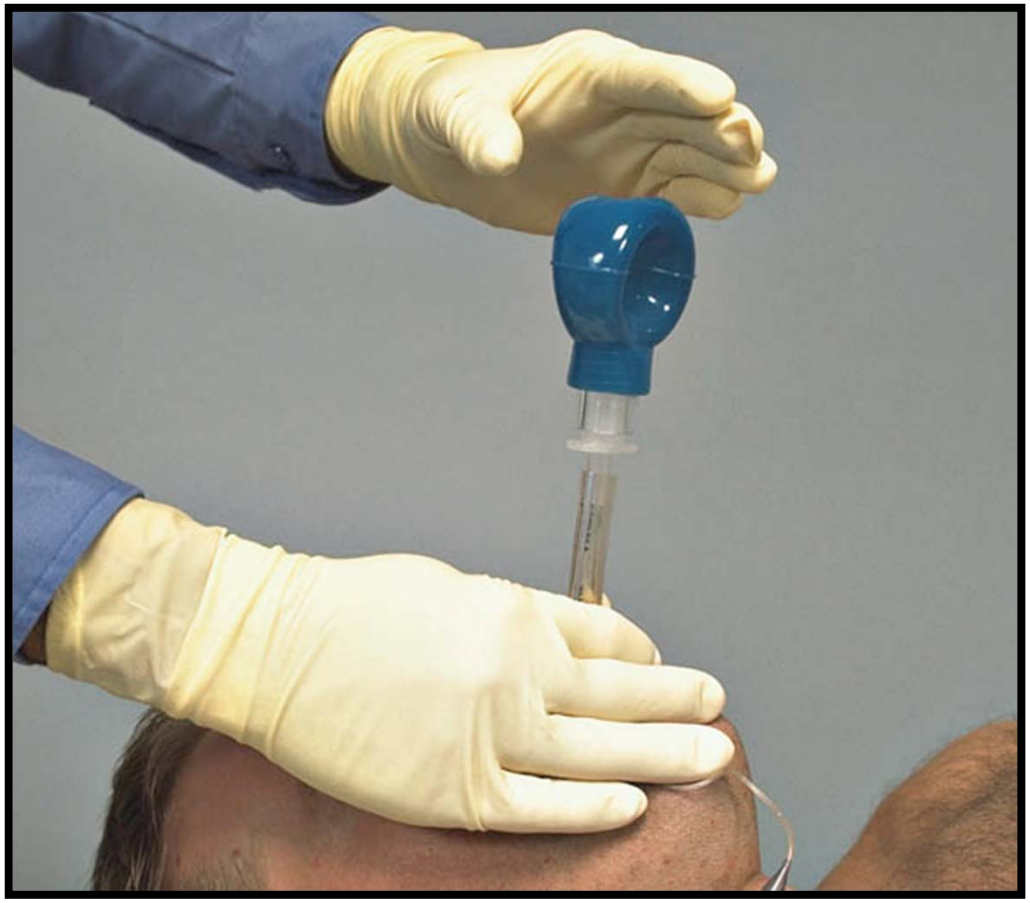

If bulb refills easily upon release, it indicates correct placement.

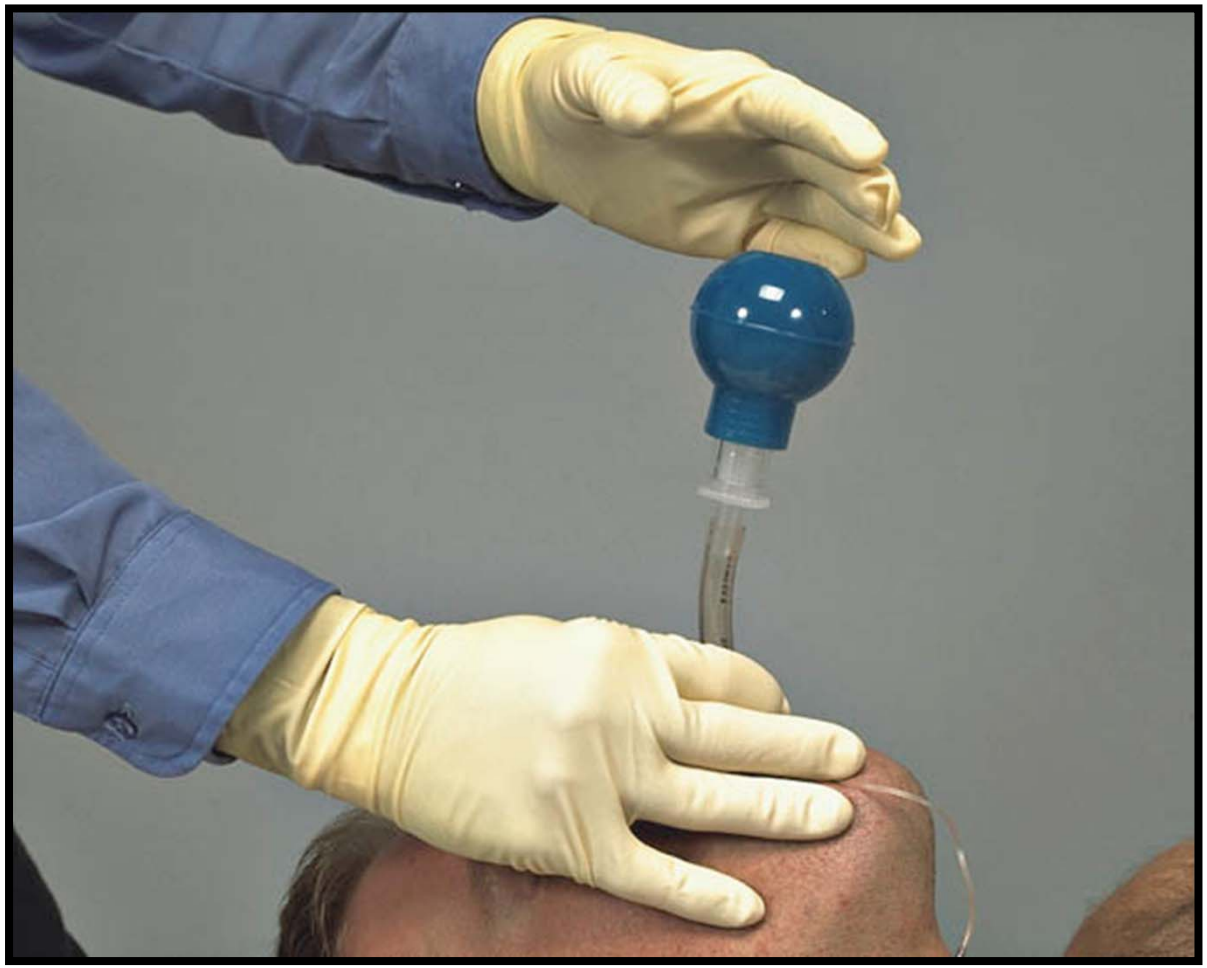

Secure tube.

Lighted stylet for endotracheal intubation

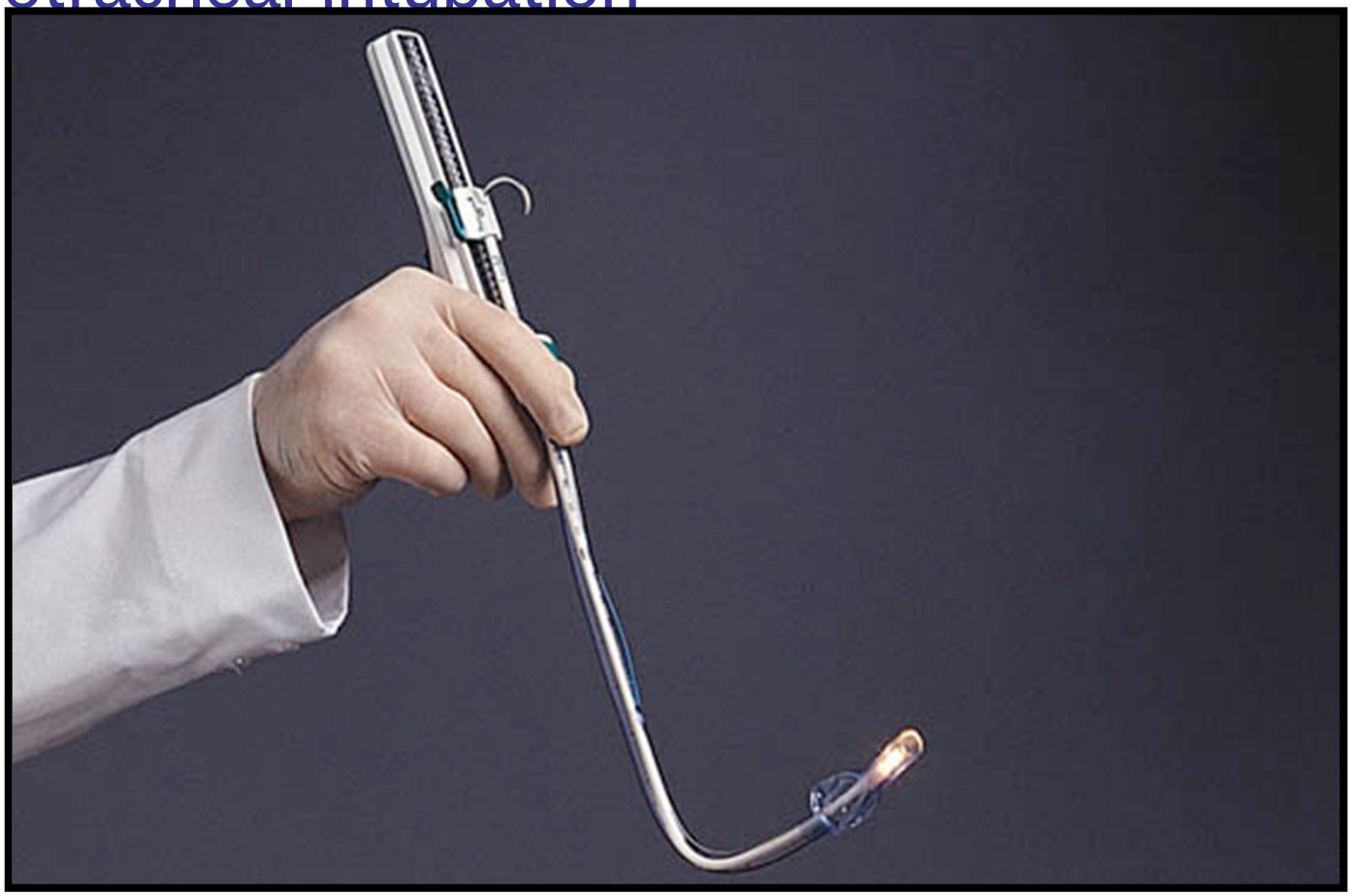

Insertion of lighted stylet/ETT

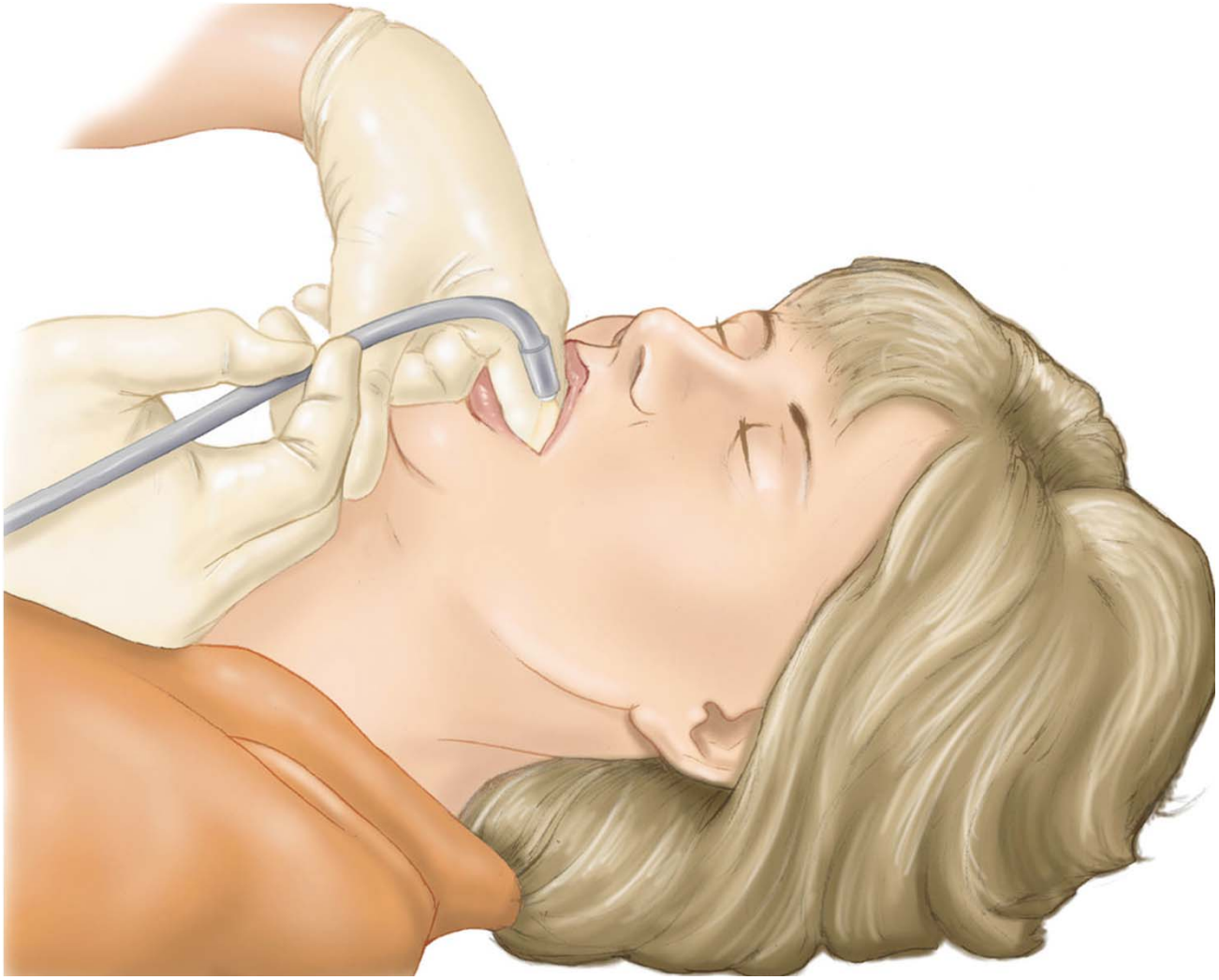

Lighted stylet/ETT in position

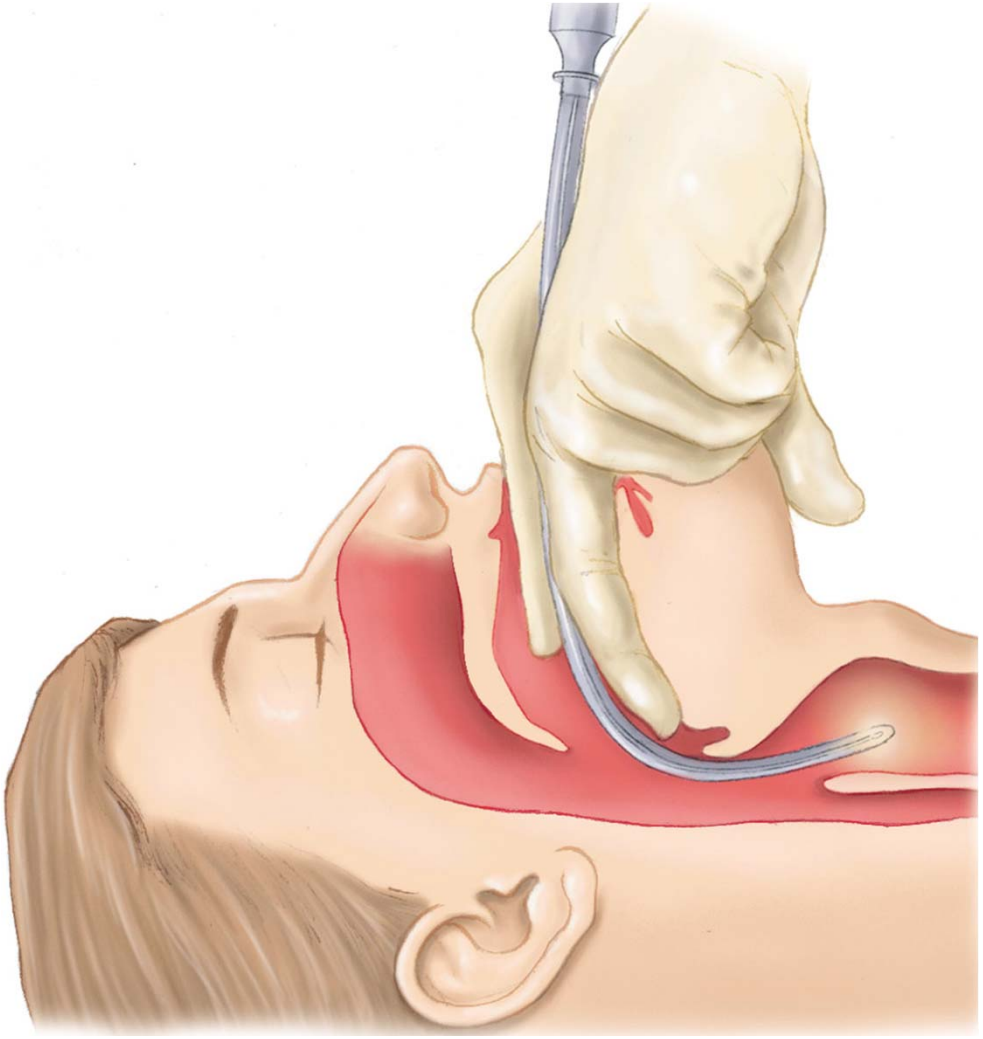

Transillumination of a lighted stylet

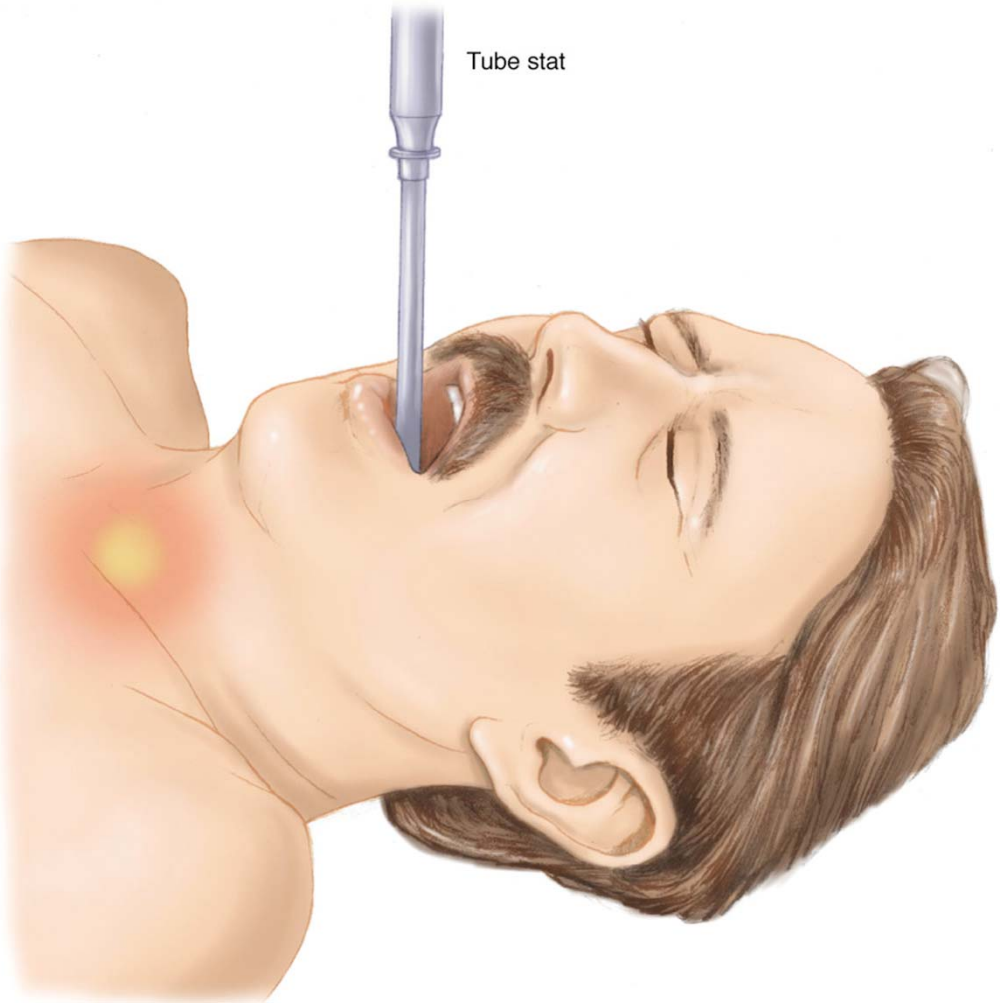

Blind orotracheal intubation by digital method

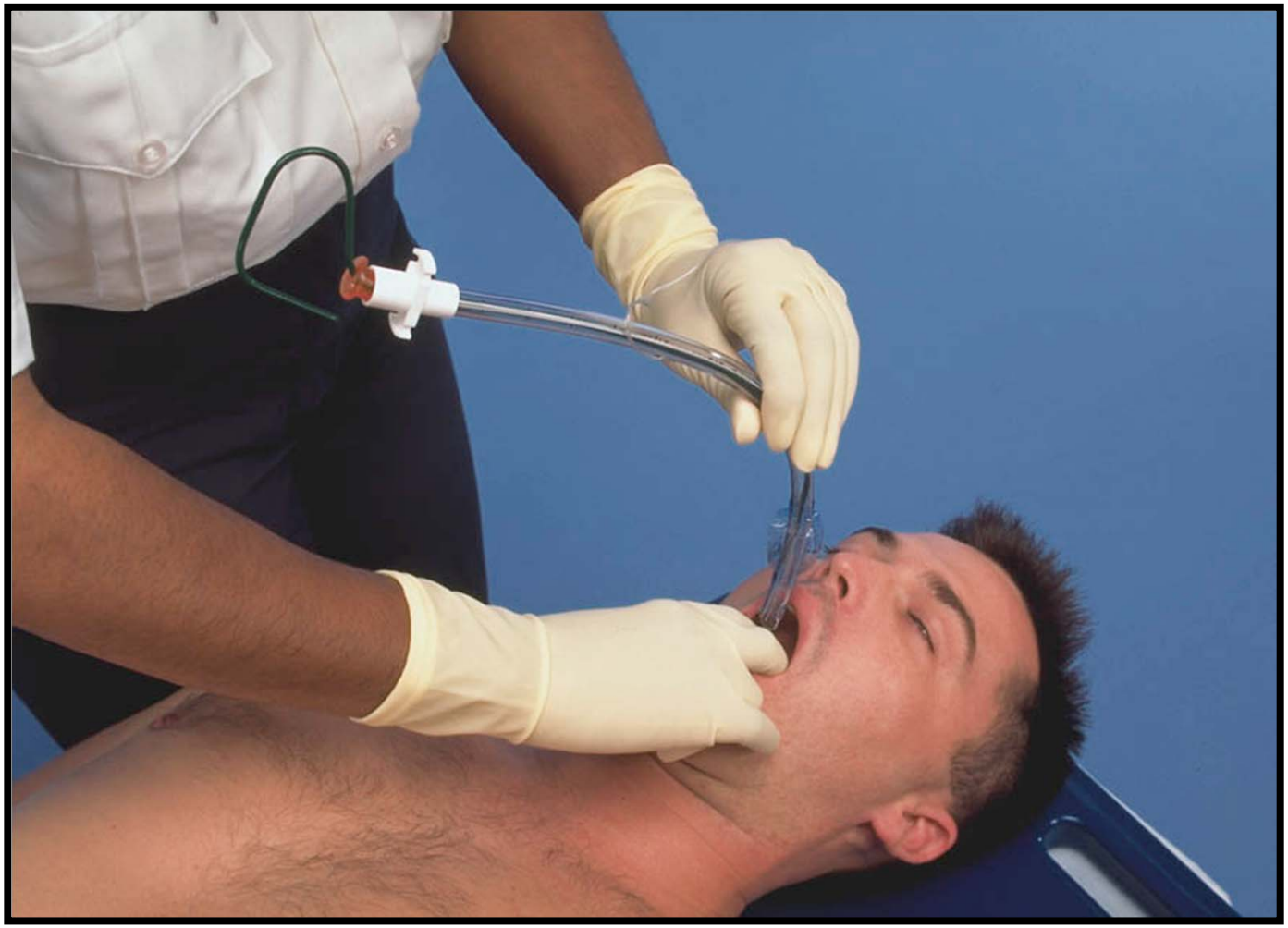

Digital Intubation (1 of 2)

Insert your middle and index fingers into patient's mouth.

Digital Intubation
(2 of 2)

Walk your fingers and palpate the patient's epiglottis.

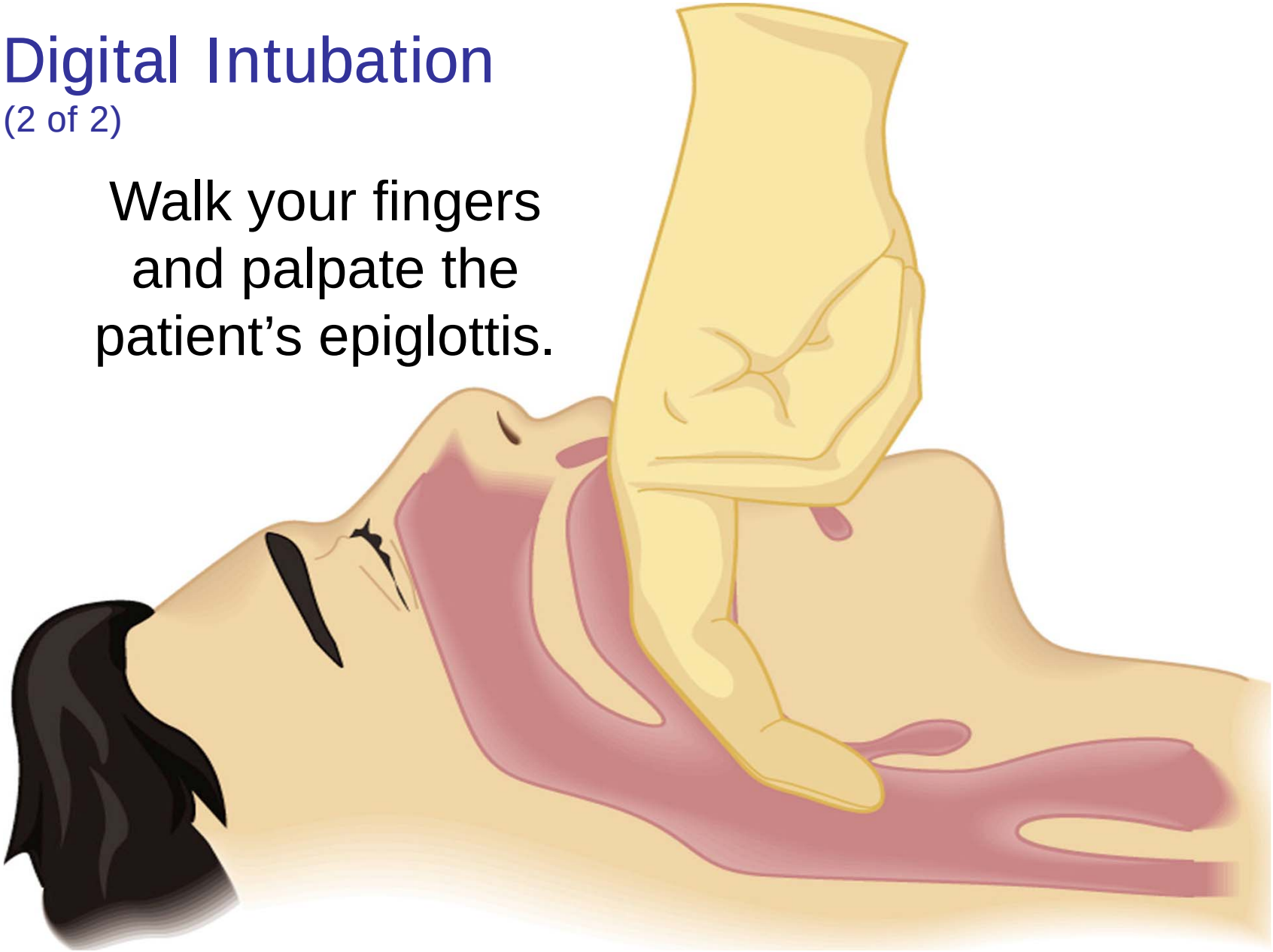

Digital intubation—insertion of the ETT

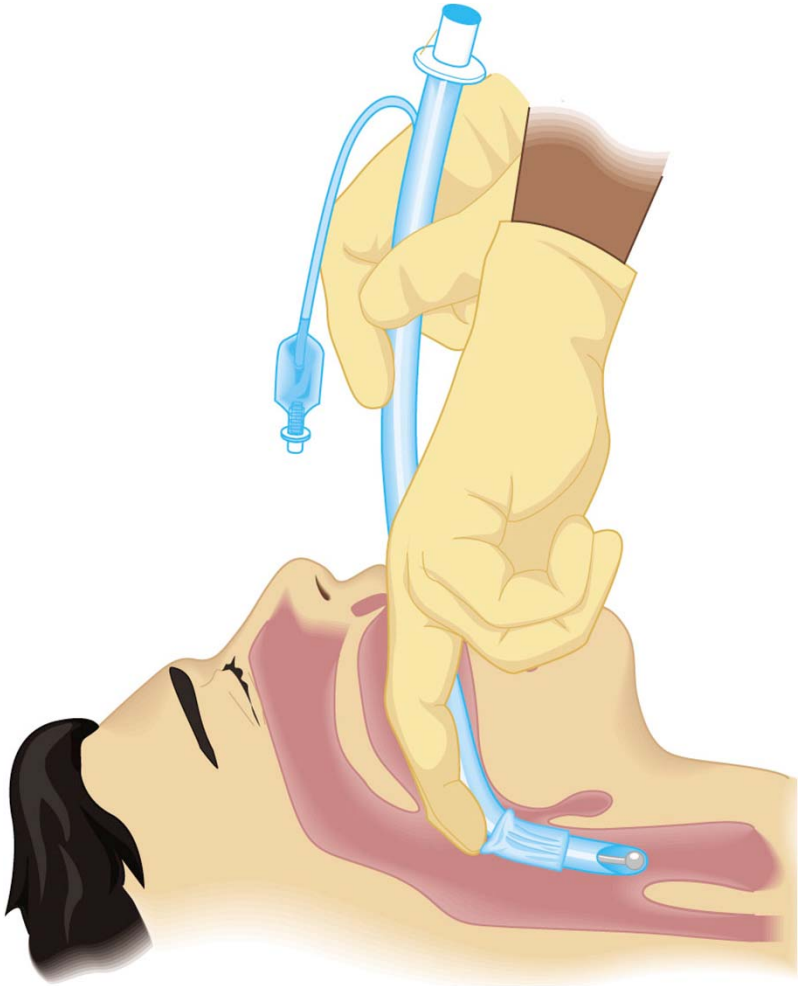

Endotracheal Intubation with In-line Stabilization

Hyperventilate patient and apply c-spine stabilization.

Apply Sellick's maneuver
and intubate.

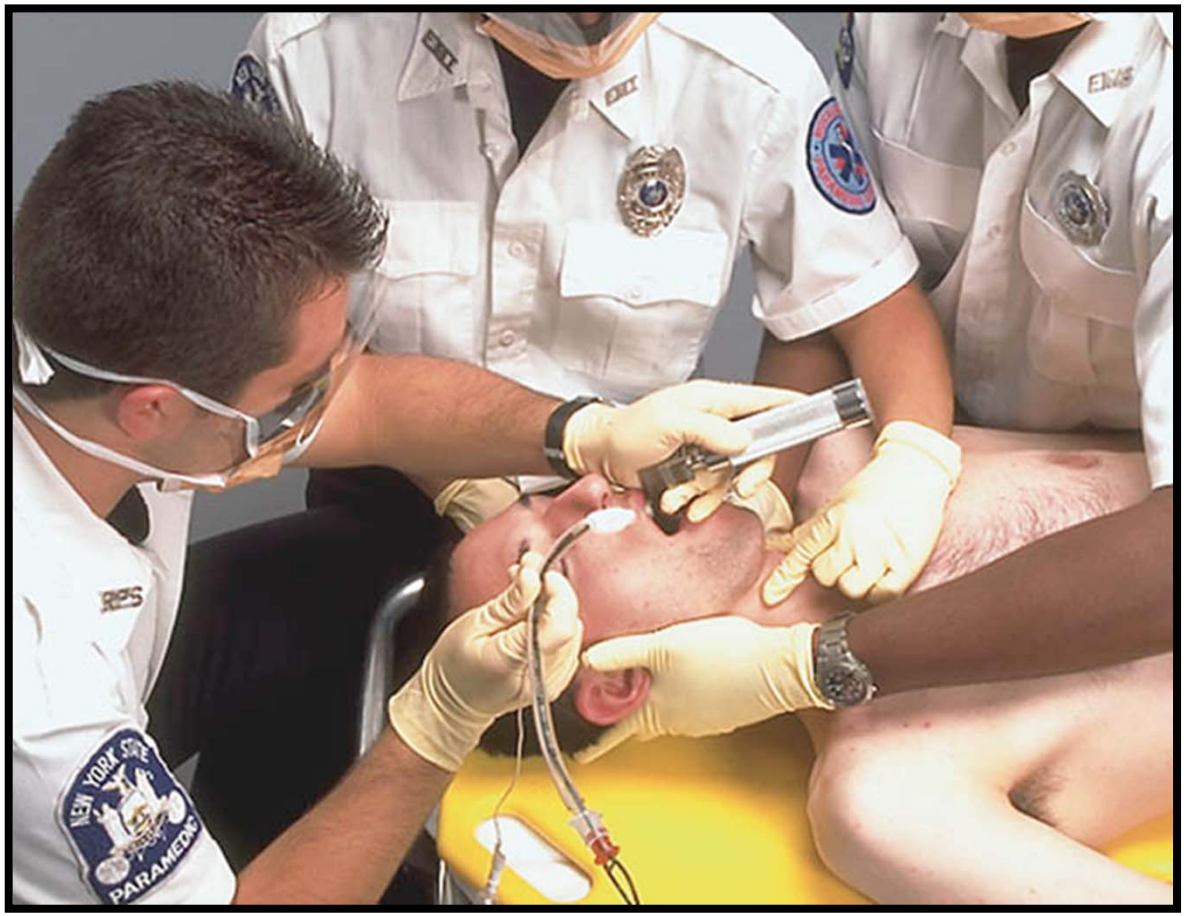

Ventilate patient
and confirm placement.

Secure ETT and
apply a cervical collar.

Reconfirm placement.

Rapid Sequence Intubation

- A patient who needs intubation may be awake. RSI paralyzes the patient to facilitate endotracheal intubation.

Guidelines for Sedative (Induction) Agents

Induction Agent	Dose	Onset	Duration (min)	Advantages	Disadvantages
Midazolam (Versed)	0.1–0.3 mg/kg	1–3 min	20–30 min	Amnesia effects, good sedative	Hypotension
Diazepam (Valium)	0.2–0.5 mg/kg	2–3 min	30–40 min	Amnesia effects	Hypotension, respiratory depression
Etomidate (Amidate)	0.3 mg/kg	1–2 min	5 min	Little effect on blood pressure, decreases intracranial pressure (ICP)	Suppresses cortisol → not good for head-injured patients
Ketamine (Ketalar)	1–2 mg/kg	≤ 1 min	10–20 min	Decreases bronchospasm, little hypotension, amnesia	Increases ICP
Sodium thiopental	3–5 mg/kg	≤ 1 min	5 min	Blunts ICP changes	Significant hypotension, bronchospasm
Propofol (Diprivan)	1–1.5 mg/kg	≤ 1 min	3–5 min	Rapid onset, good sedative effects	Significant hypotension
Fentanyl	3–5 mcg/kg	1–2 min	30–40 min	Little effect on blood pressure; blunts ICP changes	Can cause muscle rigidity in chest wall

Adjunctive RSI Agents

Agent	Dose	Indication	Contraindication Precaution
Atropine	0.01-0.02 mg/kg (min.–max./0.1–0.4)	Pediatric patients, bradycardia	Cannot give less than 0.1 mg
Lidocaine	1 mg/kg	Head injury	Allergy

Approximate Size of ETT for Pediatrics

Patient's Age	ETT Size	Type	Depth of ETT Insertion	Laryngoscope Blade Size
Premature infant	2.5–3.0	Uncuffed	8 cm	0 straight
Full-term infant	3.0–3.5	Uncuffed	8–9.5 cm	1 straight
Infant to 1 year	3.5–4.0	Uncuffed	9.5–11 cm	1 straight
Toddler	4.0–5.0	Uncuffed	11–12.5 cm	1–2 straight
Preschool	5.0–5.5	Uncuffed	12.5–14 cm	2 straight
School age	5.5–6.5	Uncuffed	14–20 cm	2 straight
Adolescent	7.0–8.0	Cuffed	20–23 cm	3 straight or curved

Endotracheal Intubation in a Child

The Pediatric Airway

- Smaller and more flexible than an adult.
- Tongue proportionately larger.
- Epiglottis floppy and round.
- Glottic opening higher and more anterior.
- Vocal cords slant upward, and are closer to the base of the tongue.
- Narrowest part is the cricoid cartilage.

Selecting ETT size according to child's age

$$\text{ETT size (mm)} = \frac{(\text{Age in years} + 16)}{4}$$

Hyperventilate the child.

Prepare the equipment.

Insert the laryngoscope.

Insert ETT and ventilate the child.

Confirm placement and secure ETT.

Reconfirm ETT placement.

Ventilation of Pediatric Patients

- Mask seal can be more difficult.
- Bag size depends on age of child.
- Ventilate according to current standards.
- Obtain chest rise and fall with each breath.
- Assess adequacy of ventilations by observing chest rise, listening to lung sounds, and assessing clinical improvement.

Nasotracheal intubation may be useful in some situations:

- Possible spinal injury
- Clenched teeth
- Fractured jaw, oral injuries, or recent oral surgery
- Facial or airway swelling
- Obesity
- Arthritis preventing sniffing position

Advantages of Nasotracheal Intubation

- The head and neck can remain in neutral position.
- It does not produce as much gag response and is better tolerated by the awake patient.
- It can be secured more easily than an orotracheal tube.
- The patient cannot bite the ETT.

Disadvantages of Nasotracheal Intubation

- More difficult and time-consuming to perform than orotracheal intubation.
- Potentially more traumatic for patients.
- Tube may kink or clog more easily than an orally placed tube.
- Poses a greater risk of infection.
- Improper placement is more likely when performing blind nasotracheal intubation.
- Blind nasotracheal intubation requires that the patient be breathing.

Nasotracheal Intubation

Is considered “unacceptable” by NYC REMAC.

Blind nasotracheal intubation

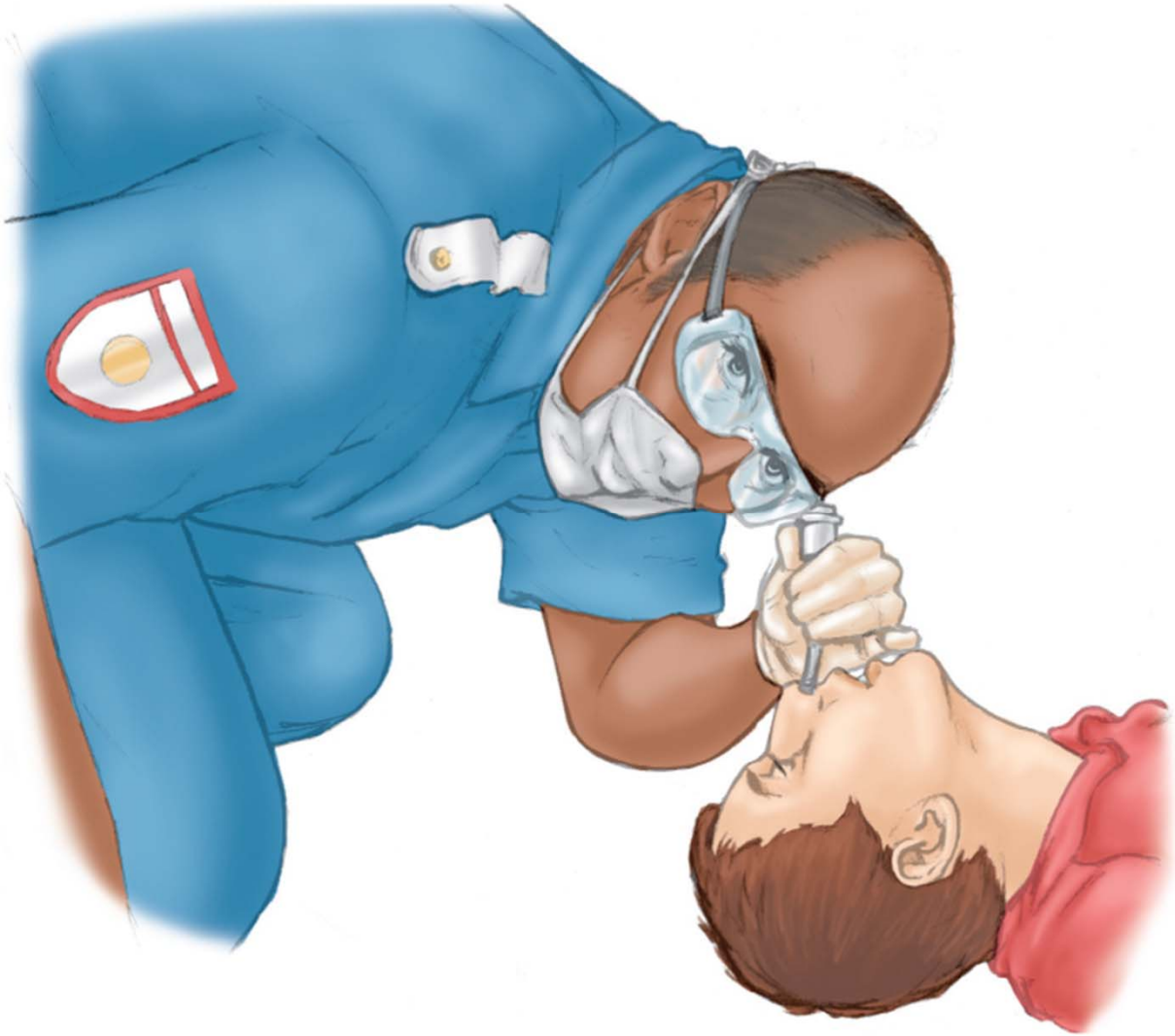

Other Intubation Devices

- Esophageal Tracheal **CombiTube** (ETC)
- Pharyngo-tracheal Lumen (PtL)
- Laryngeal Mask Airway (LMA)
- ****** King Airway ******
- Intubating Laryngeal Mask Airway (iLMA)
- Cobra Perilaryngeal Airway (CobraPLA)
- Ambu Laryngeal Mask (ALM)
- Esophageal Gastric Tube Airway (EGTA)
- Esophageal Obturator Airway (EOA)

ETC airway – esophageal placement

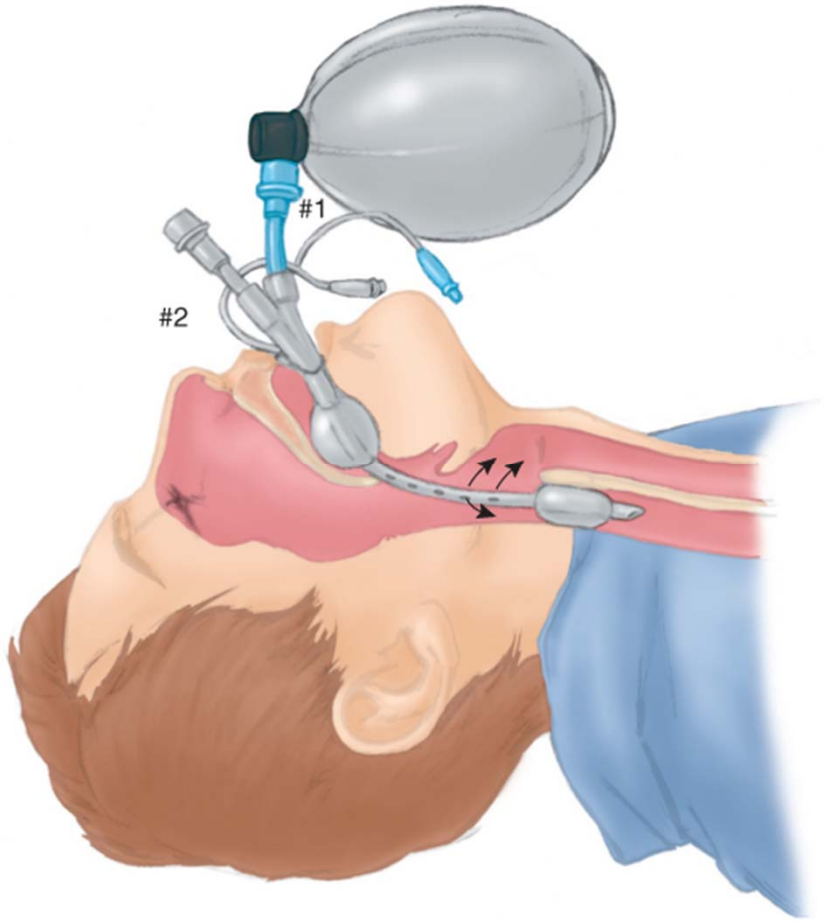

ETC airway – tracheal placement

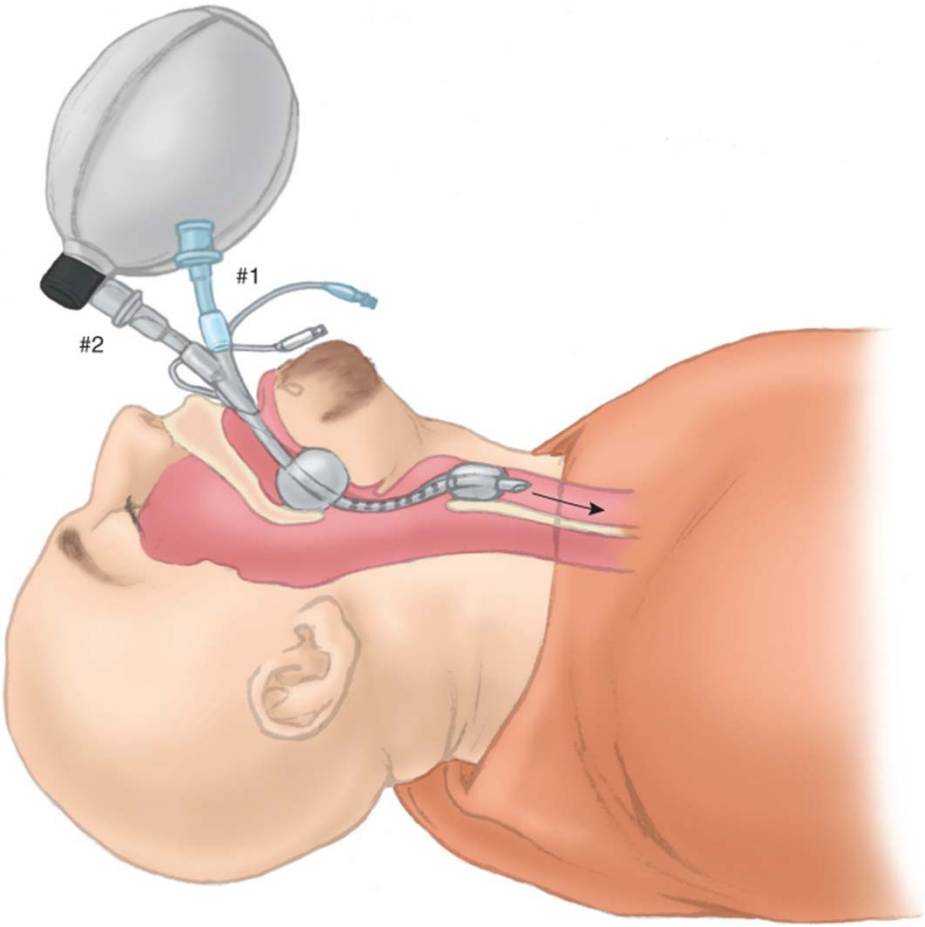

Pharyngo-tracheal lumen airway

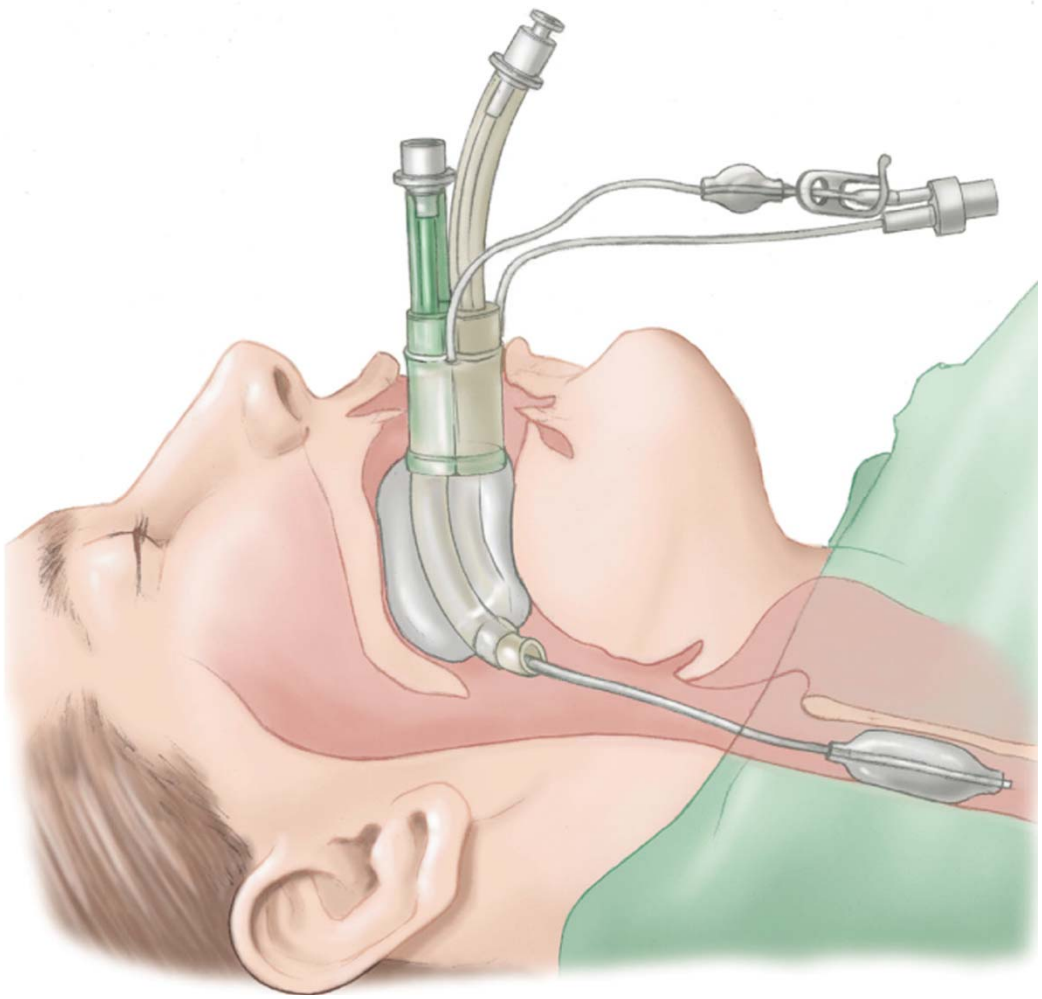

Laryngeal mask airway

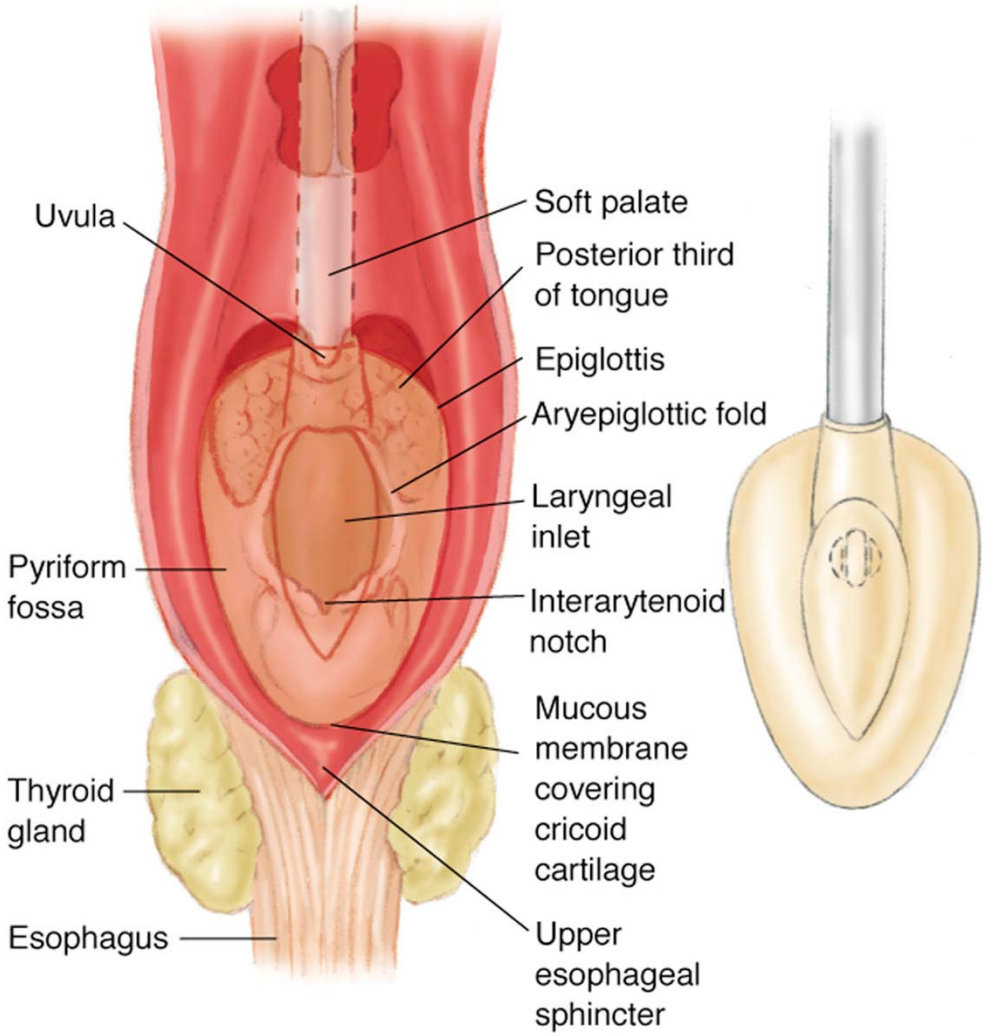

Intubating laryngeal mask airway

LMA North America

Cobra perilaryngeal airway

Engineered Medical Systems, Inc.

Supralaryngeal device designed to be positioned in the hypopharynx where it abuts the structure of the laryngeal inlet

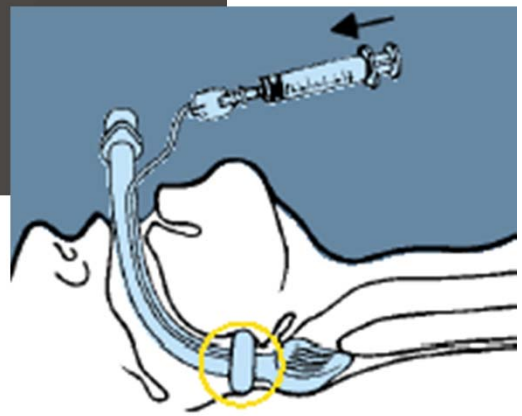

Ambu laryngeal mask

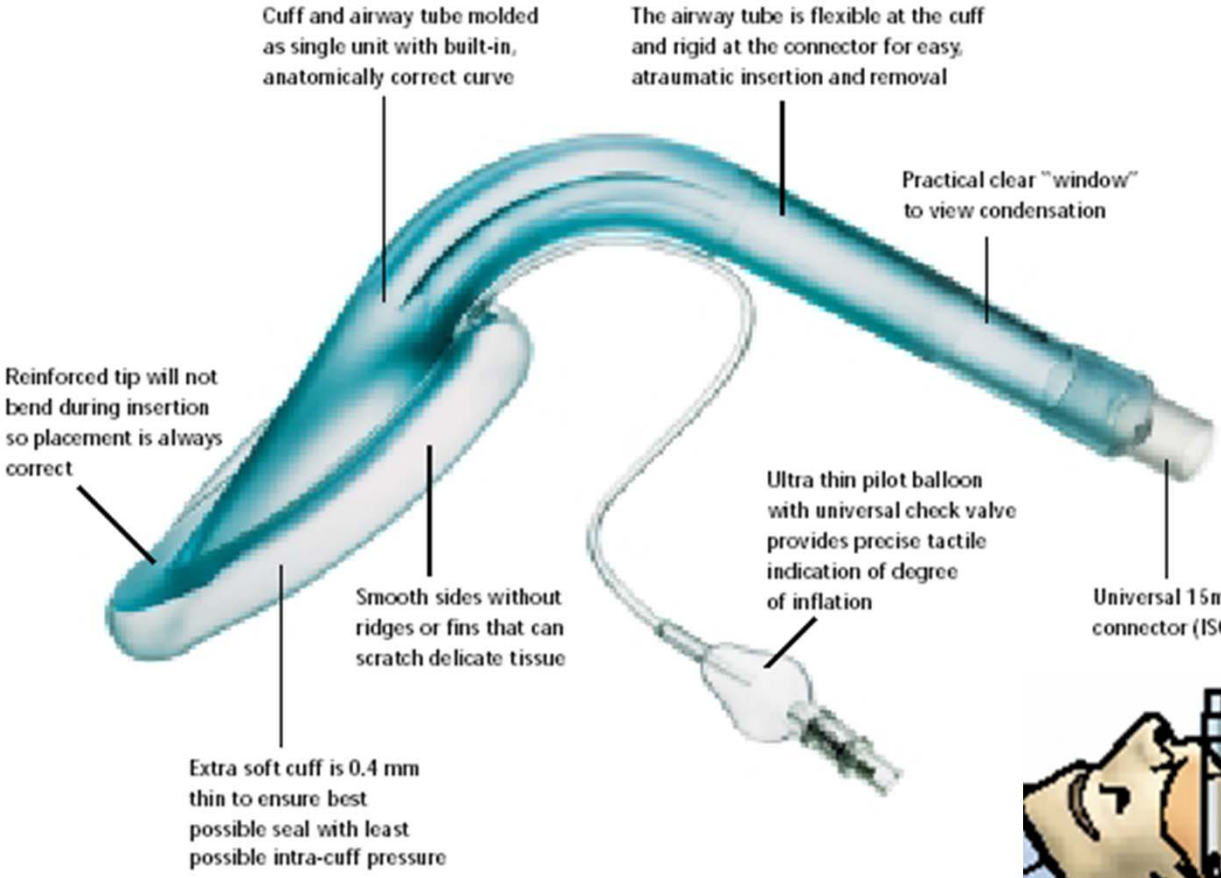

Continuously recheck
and reconfirm the placement of
the endotracheal tube.

King Airway

Definition

- The King airway is a single use device intended for airway management.
- May be used by AEMTs in the prehospital setting, who have been trained in the indications, contraindications and application of the devise.
- At some point might be used by EMTs??

Description

- A curved tube with ventilation ports between two inflatable cuffs.
- The distal cuff is designed to seal the esophagus.
- The proximal cuff is designed to seal the oropharynx.
- At the proximal end of the tube is a 15mm connector to be used with standard breathing circuit or resuscitation bag.

Size determi
by Pt's heigh

- **Yellow: 4-**
- **Red: 5-6 ft**
- **Purple: >**

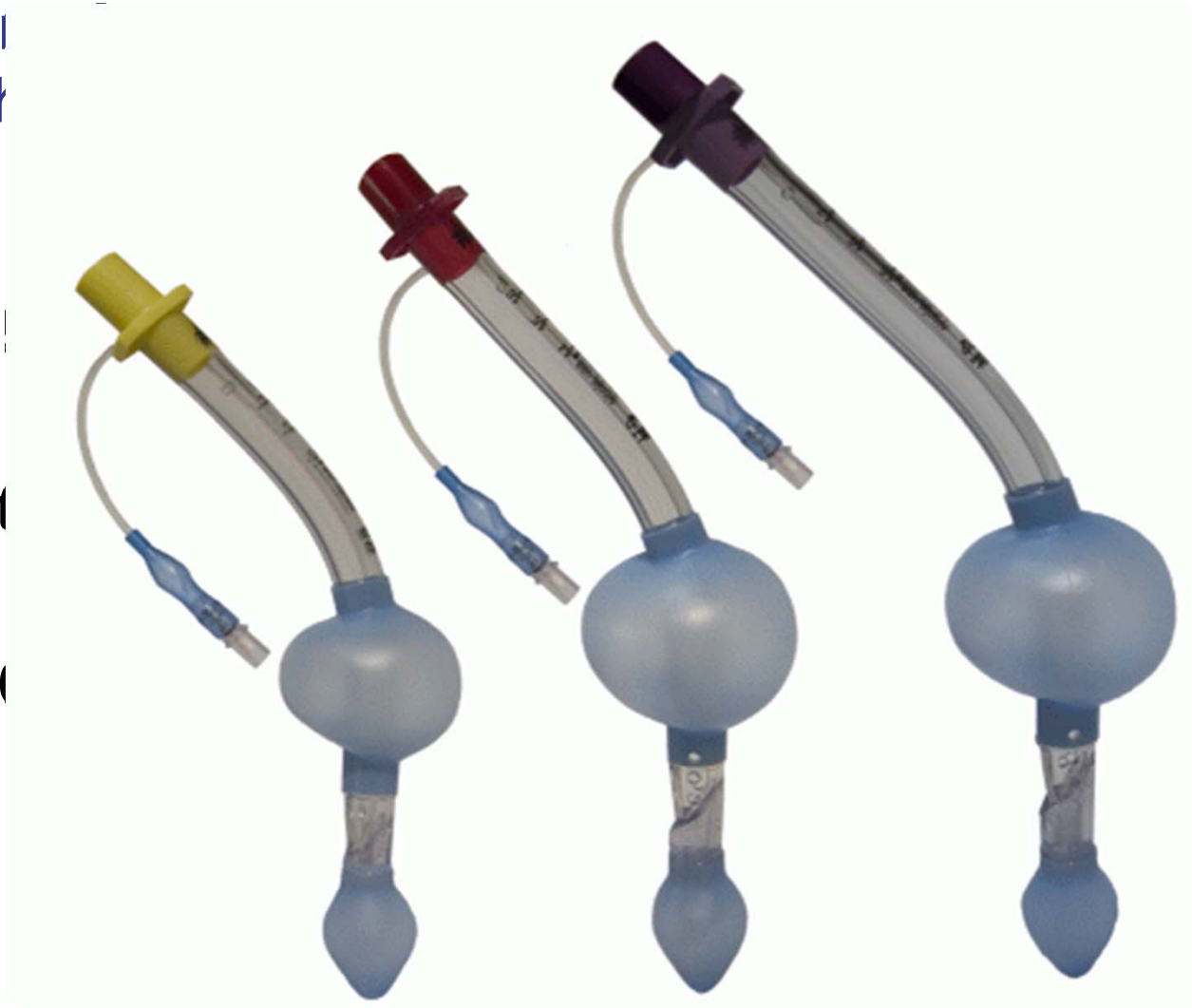

Indications

- To promote airway management by providing a patent airway in the unconscious, apneic patient.
- The King airway is latex free product.

Contraindications

- Responsive patients with an intact gag reflex.
- Patients with known esophageal disease, i.e. esophageal varices.
- Patients known or suspected to have ingested caustic substances.

Precautions:

- Vomiting and aspiration
- Excess pressure in abdomen

Instructions for use

- Choose appropriate size based on patient's height.
- Test cuffs by inflating to recommended volume of air and deflate cuffs completely before attempting to insert.
- Generously lubricate tube using a water based lube.
- Pre-oxygenate patient with 100% O2
- Have suction available.

Insertion:

- Position the head in a slightly sniffing position, unless spinal injury is known or suspected, then maintain cervical alignment and keep the head in a neutral position.
- Insert King rotated 45-90 degrees laterally and insert into mouth
- As you gently advance the tube rotate tube to midline.
- Advance tube until base of connector aligns with teeth or gums.

Cuff inflation:

- Inflate cuffs with minimum volume necessary to seal the airway according to tube size.
- Attach to resuscitator bag and ventilate using 100% O2 source.
- Assure chest rise and fall. Auscultate breath sounds.
- Secure tube, using a commercially approved device, noting depth of tube placement.
- Monitor end tidal CO2 if available.

Documentation:

- In PCR.
- Note time, size and depth of tube placement.
- Patient response to procedure.
- Skills and medication usage form to NorCal EMS.

Remember:

- When placing a King airway during CPR minimize interruption of CPR and place tube while CPR is in progress.
- If spinal injury is known or suspected, maintain a neutral head alignment and initiate cervical spine precautions concurrently with airway management.

Foreign body removal with direct visualization and Magill forceps

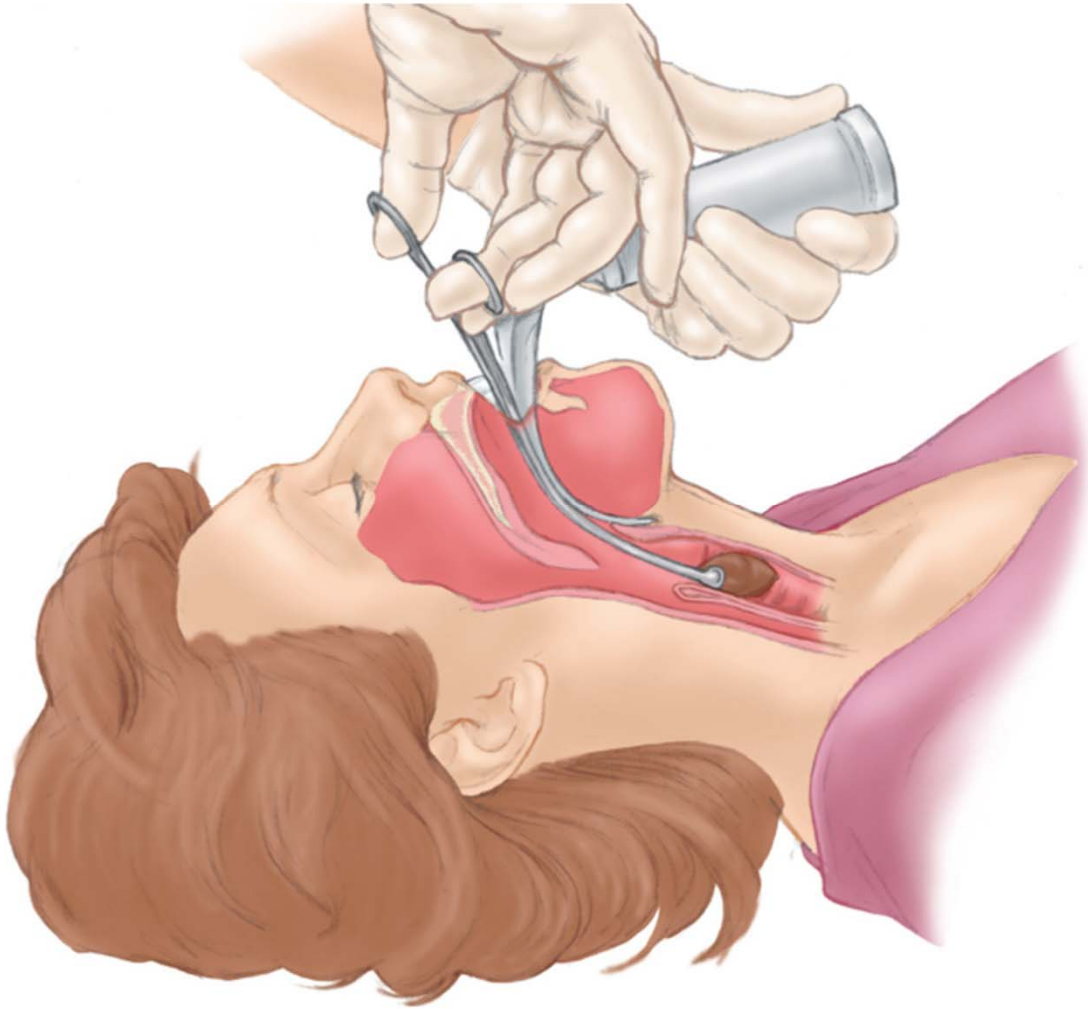

Magill forceps

The only indication
for a surgical airway is
the inability to establish an
airway by any other method.

Direct visualization of the larynx with a laryngoscope may enable the removal of an obstructing foreign body.

Anatomical landmarks for cricothyrotomy

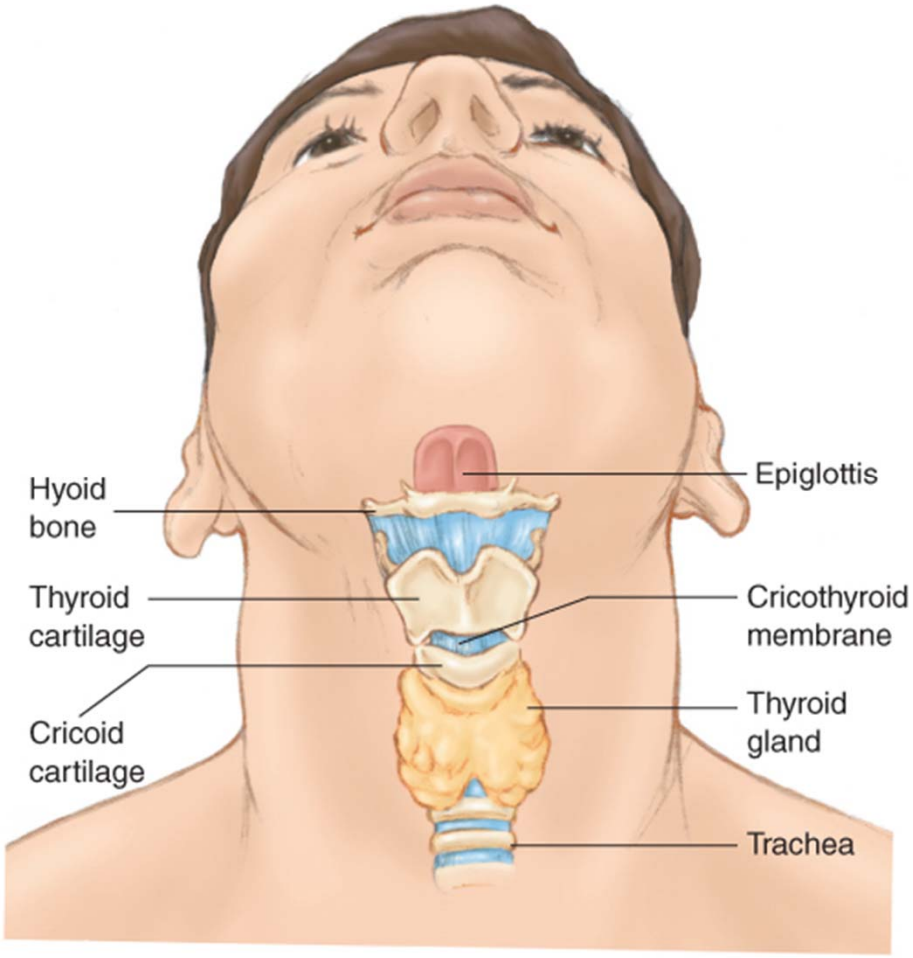

Locate/palpate
cricothyroid membrane.

Proper positioning for cricothyroid puncture

Advance the catheter
with the needle.

Cannula properly placed in trachea

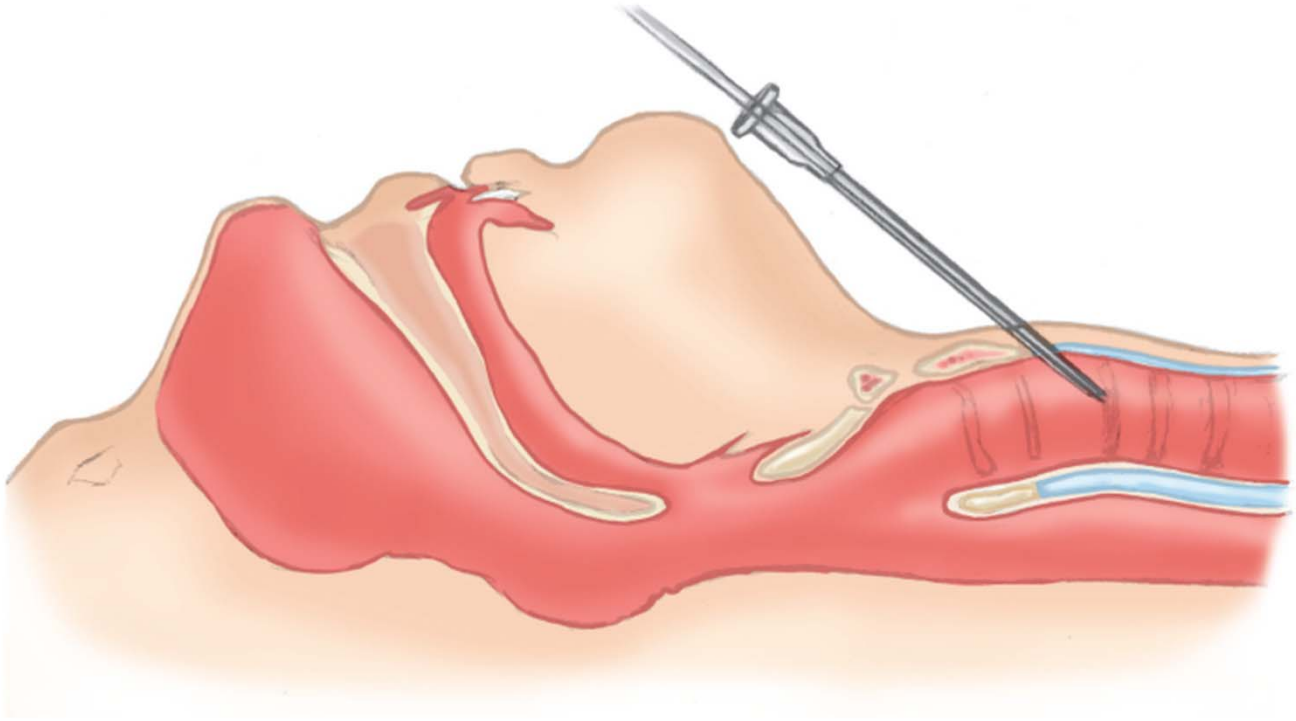

Jet ventilation with needle cricothyrotomy

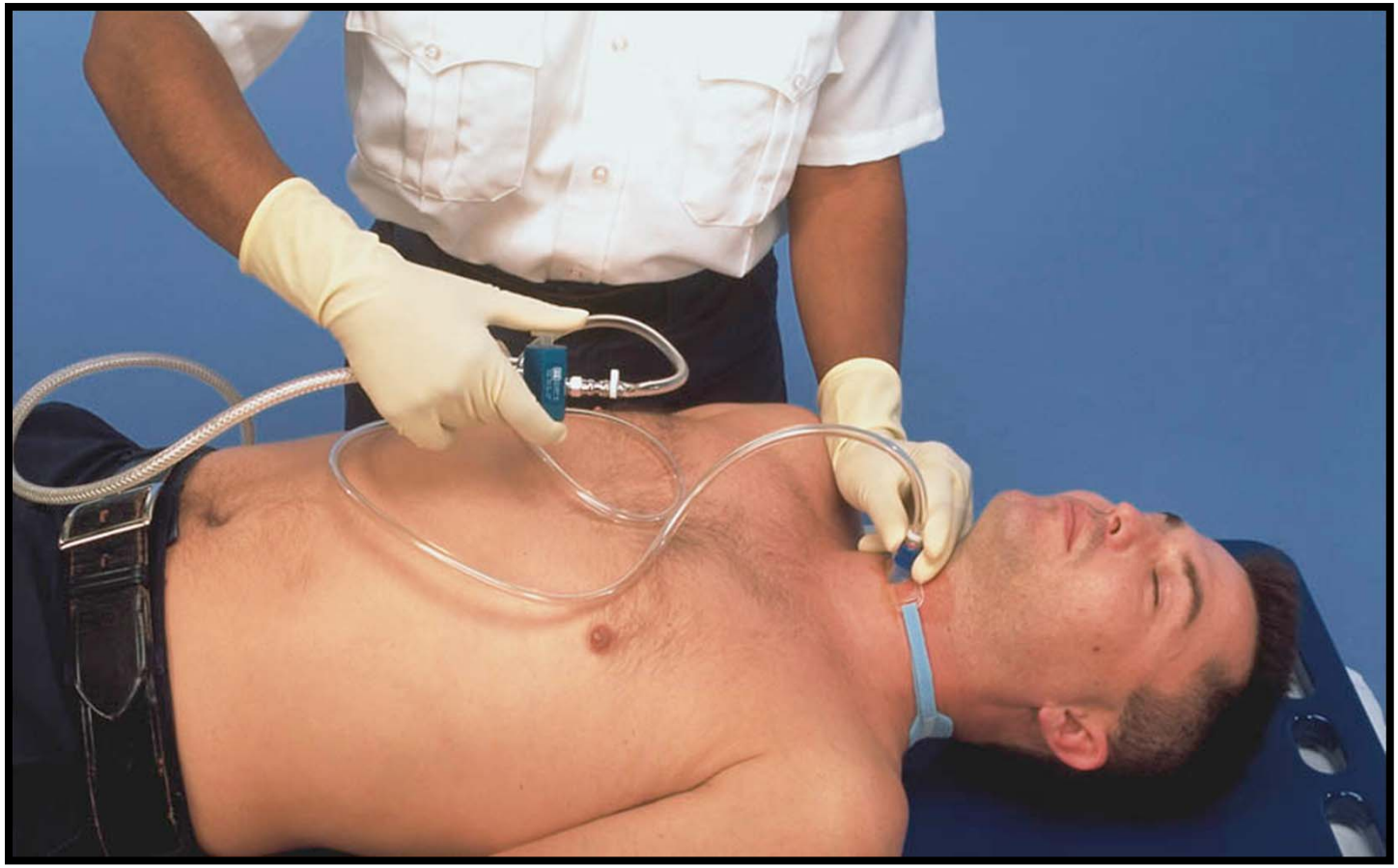

Open Cricothyrotomy

Locate cricothyroid membrane.

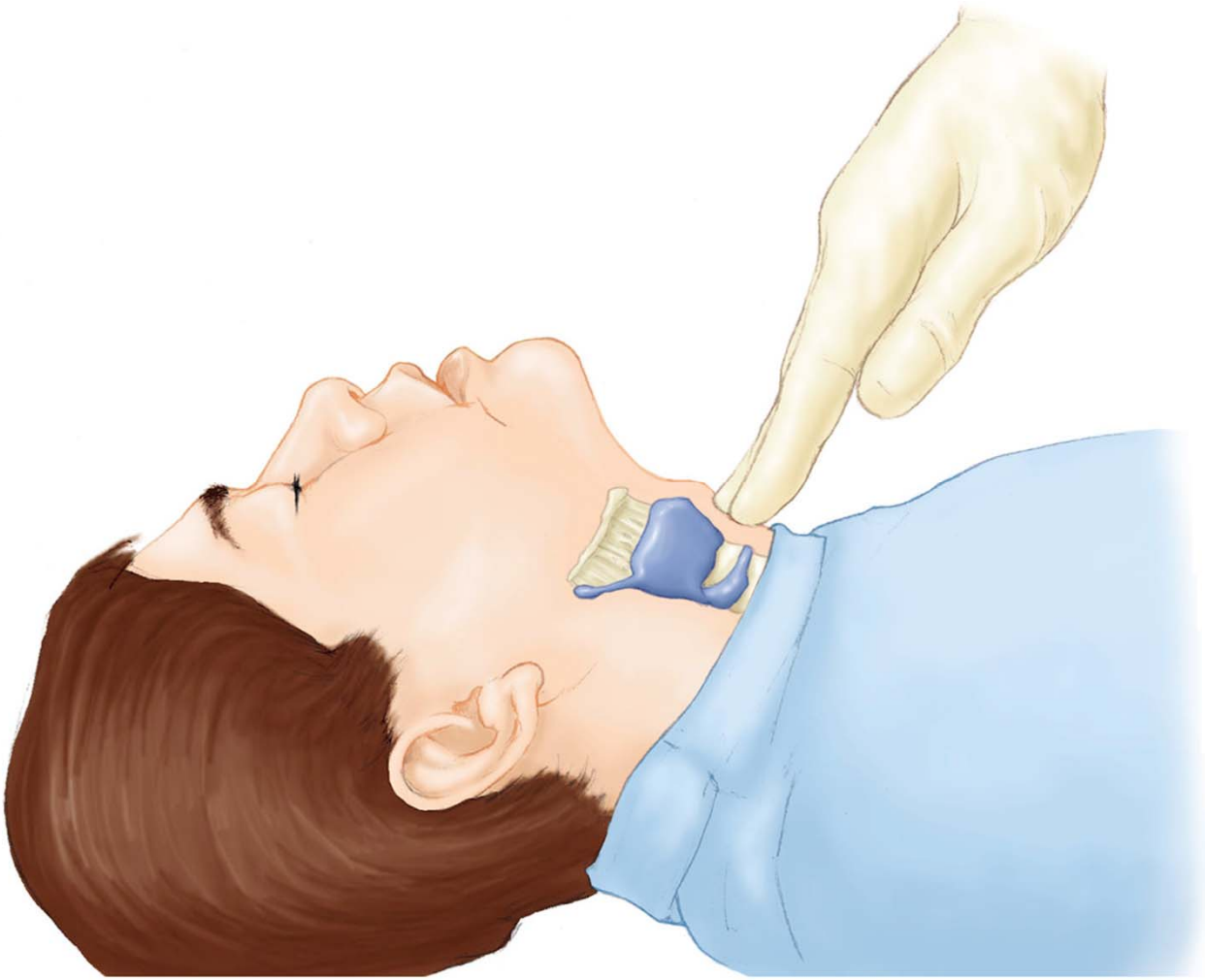

Stabilize larynx and make a 1–2 cm skin incision over cricothyroid membrane.

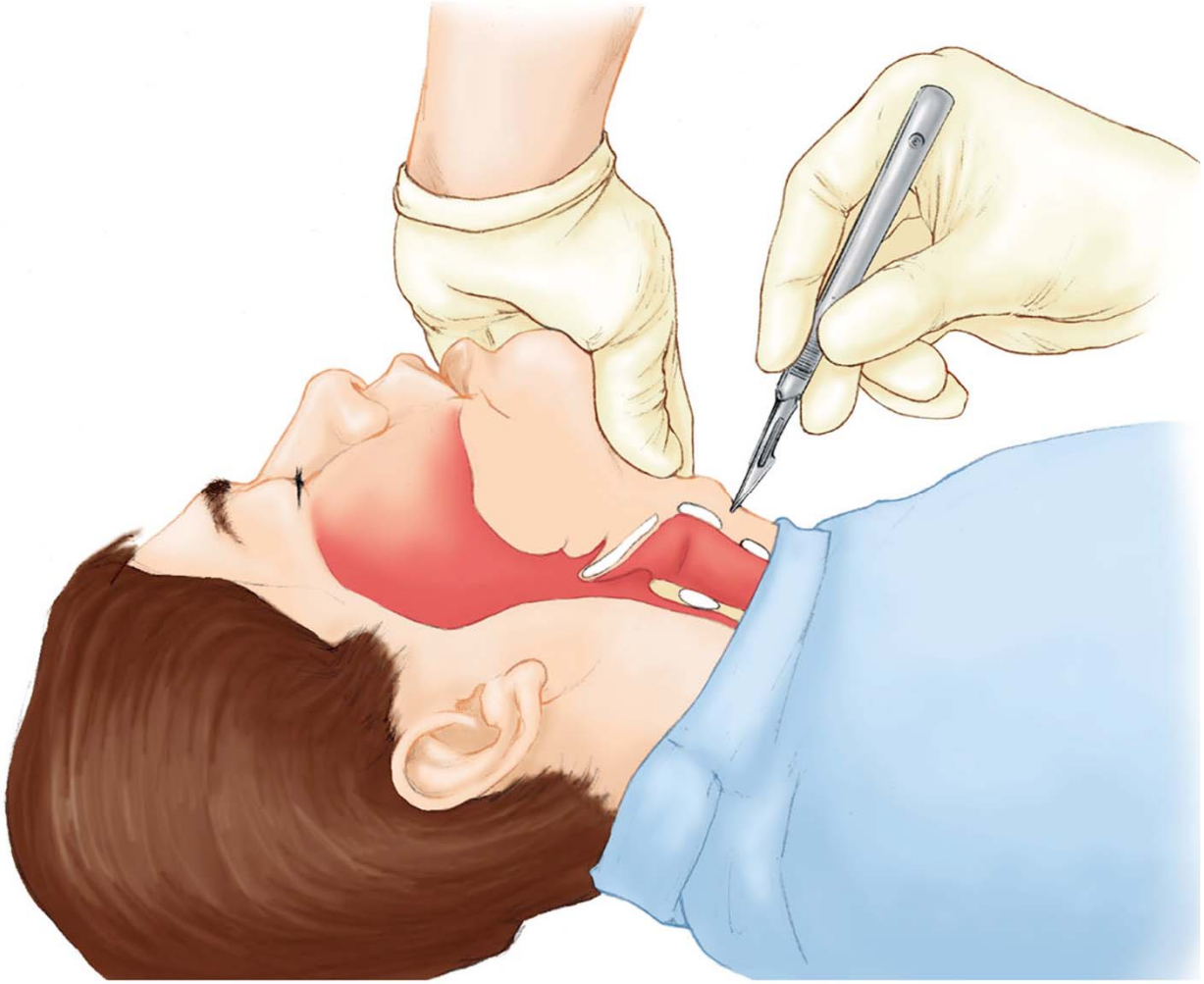

Make a 1 cm horizontal incision through the cricothyroid membrane.

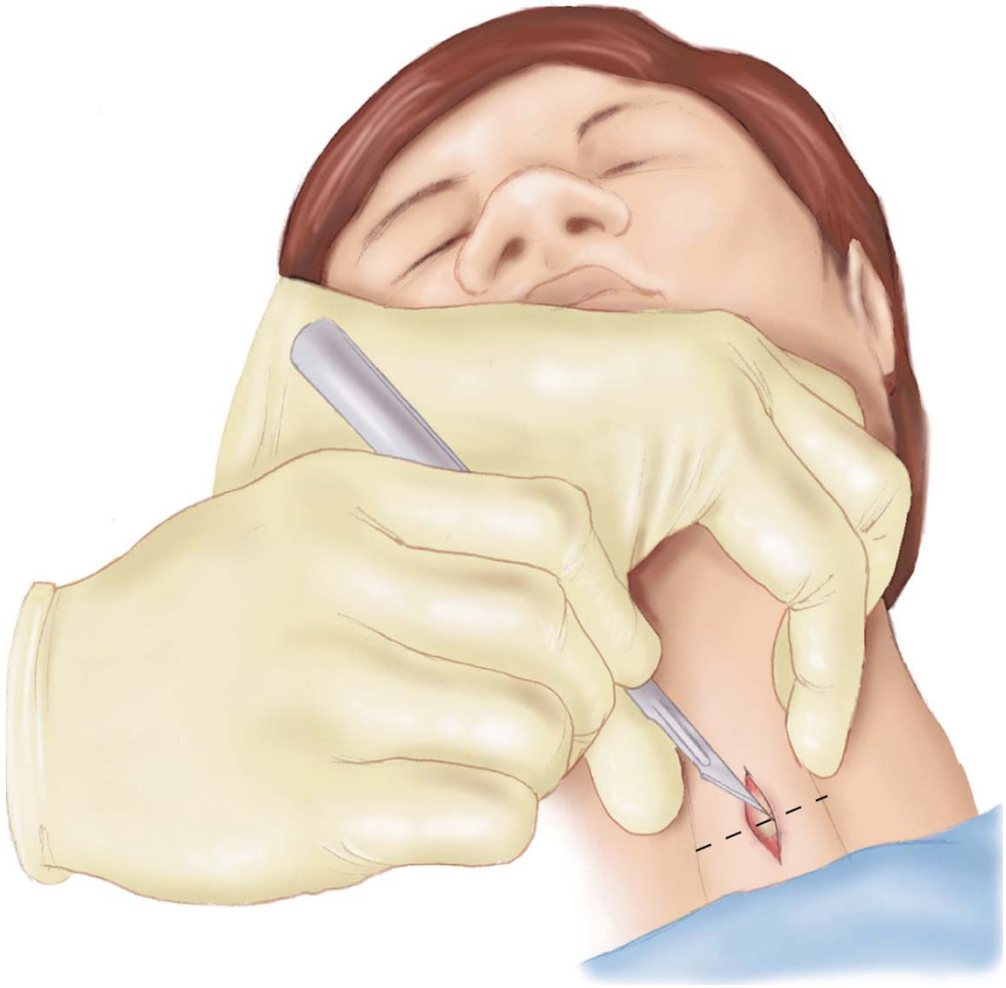

Using a curved hemostat,
spread membrane incision open.

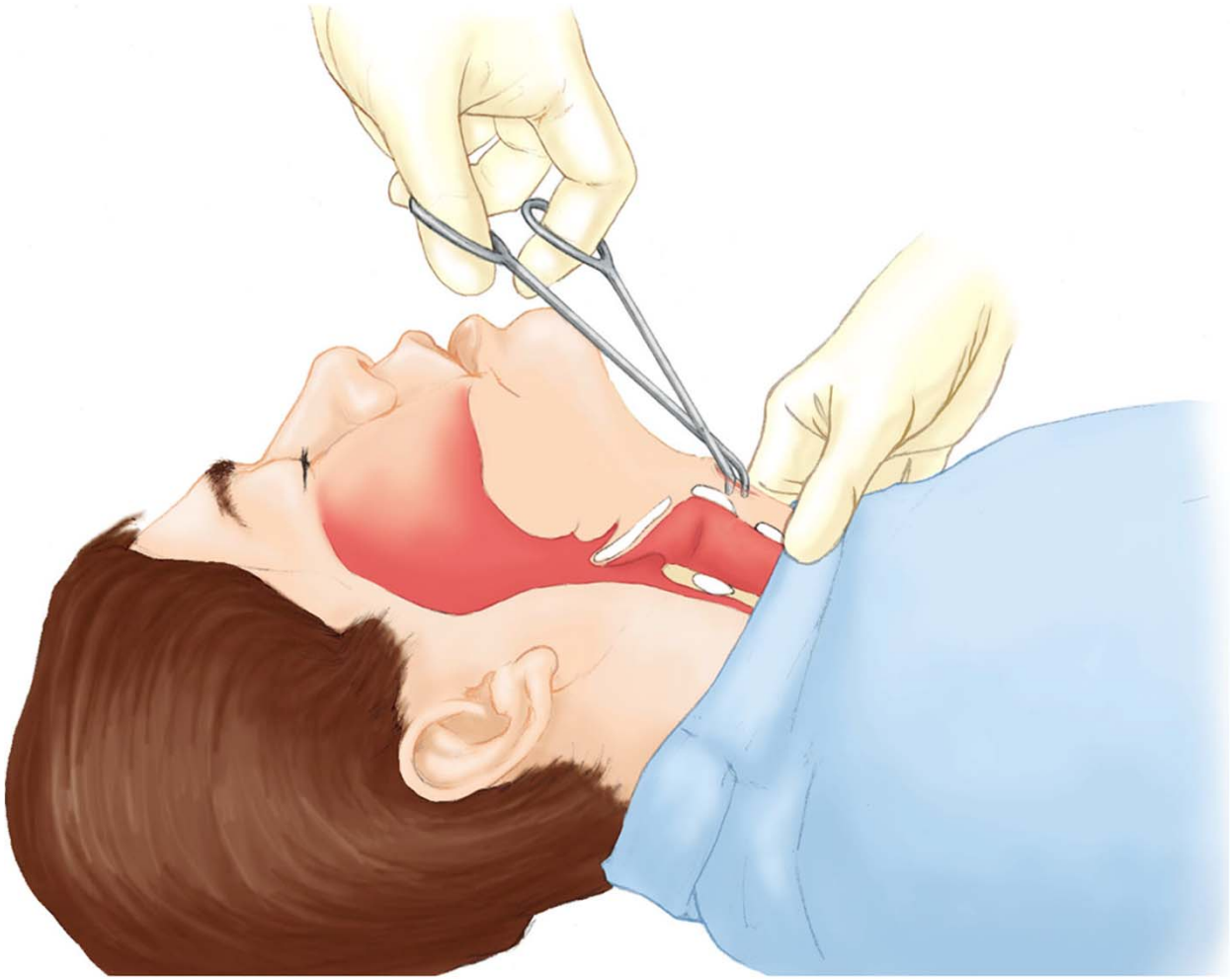

Insert an ETT (6.0)
or Shiley (6.0).

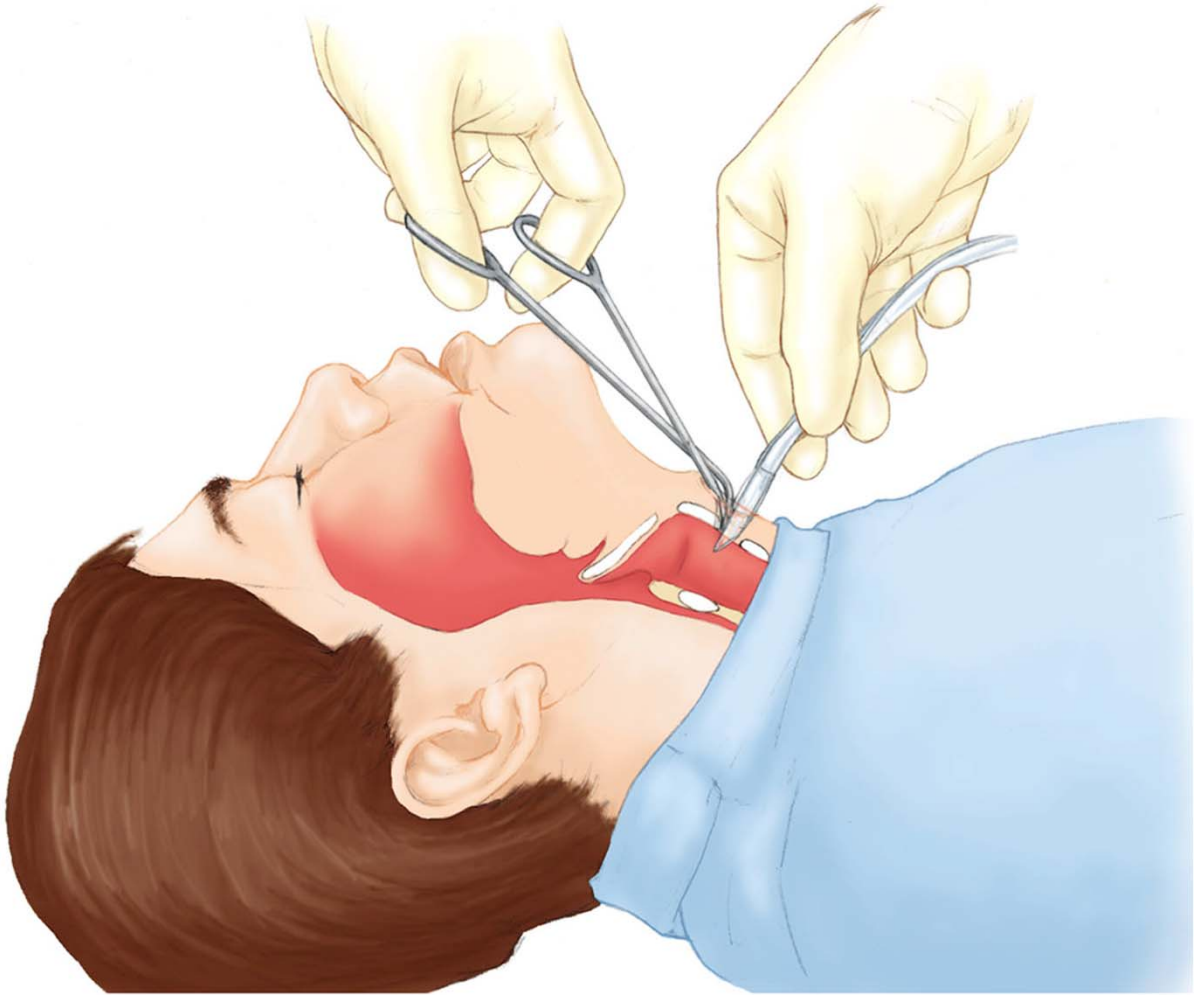

Inflate the cuff.

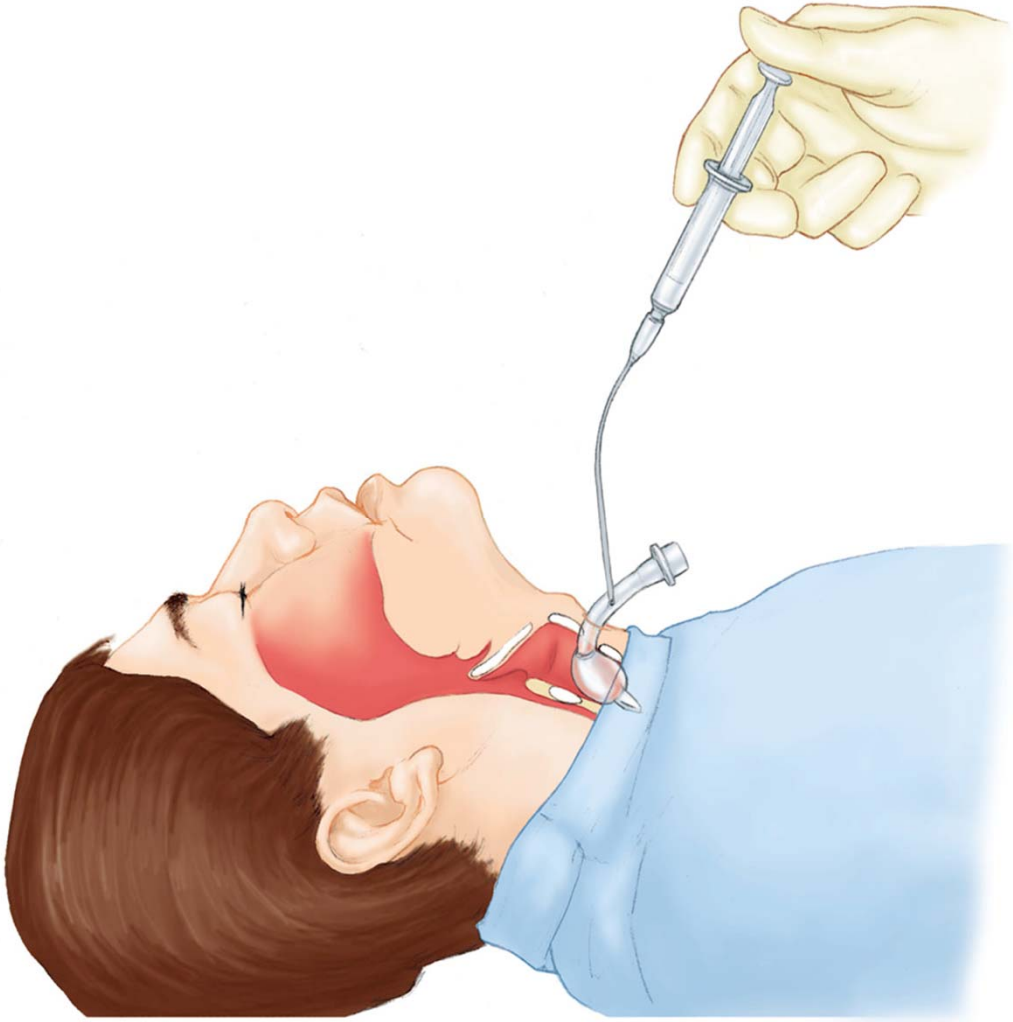

Confirm placement.

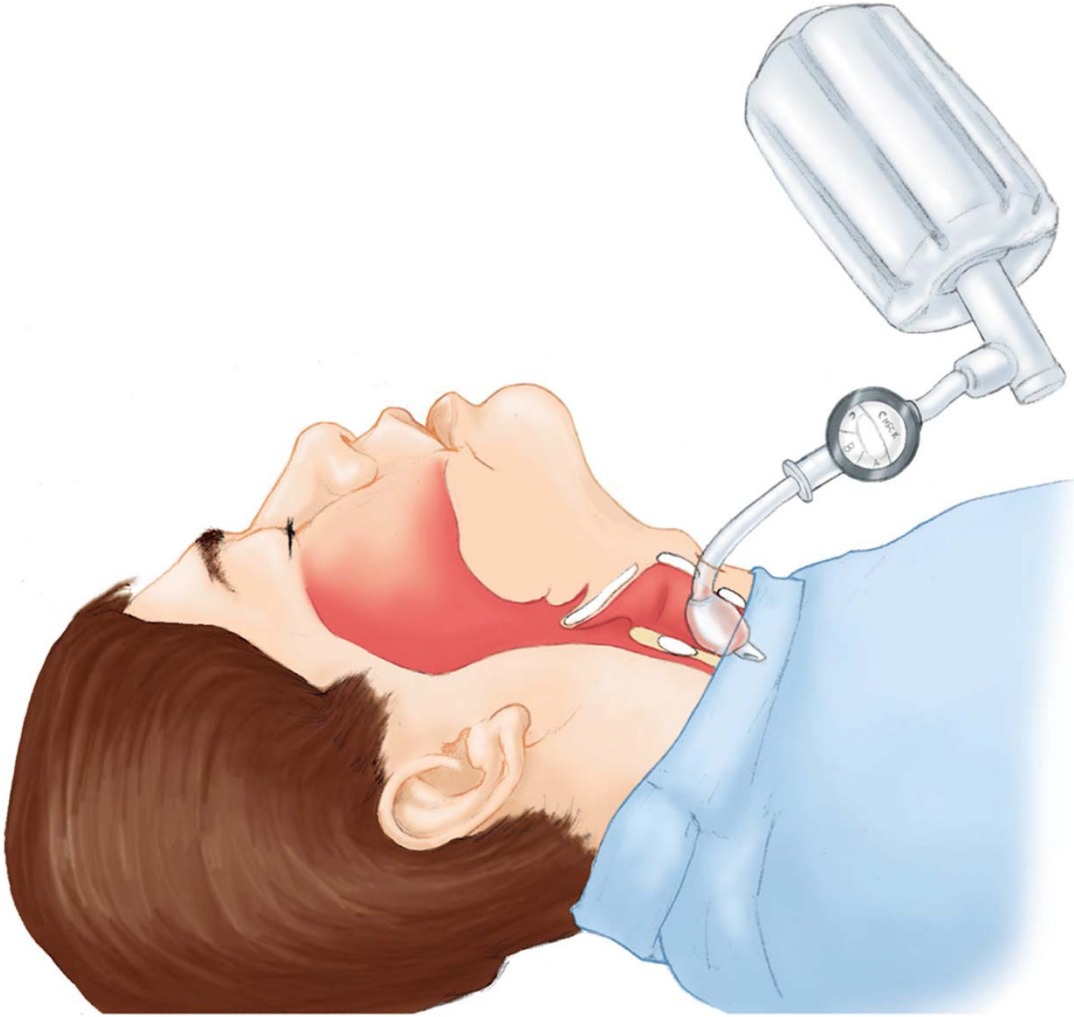

Ventilate.

Secure tube, reconfirm placement, evaluate patient.

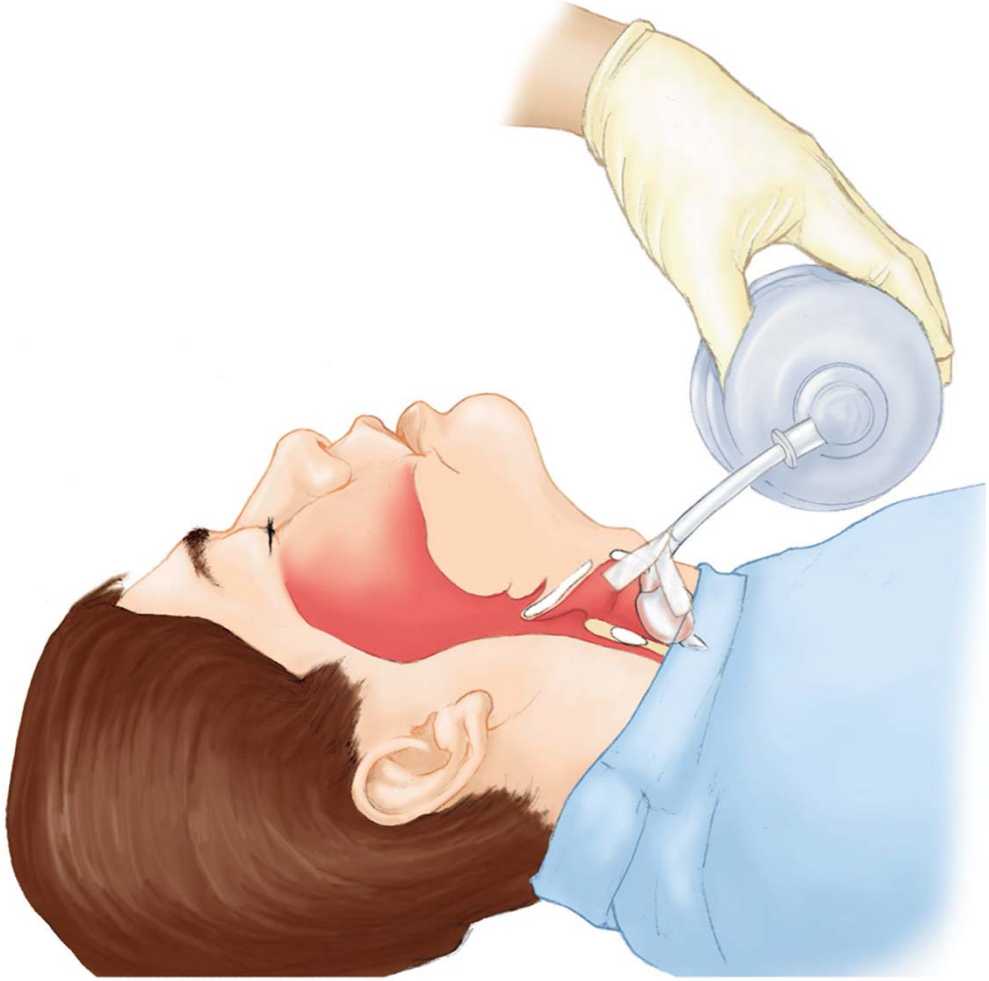

Tracheostomy cannulae

Patients with Stoma Sites

- Patients who have had a laryngectomy or tracheostomy breathe through a stoma.
- There are often problems with excess secretions, and a stoma may become plugged.

Suctioning

- Anticipating complications when managing an airway is the key for successful outcomes.
  - Be prepared to suction all airways to remove blood or other secretions and for the patient to vomit.

Advantages and Disadvantages of Various Suction Types

Type	Advantages	Disadvantages
Hand-powered	Lightweight, portable, inexpensive, simple to operate	Limited volume, manually powered, fluid contact components are not disposable
Oxygen-powered	Small, lightweight	Limited suction power, uses a lot of oxygen
Battery-operated	Lightweight, portable, excellent suction power, simple to operate and troubleshoot in the field	Battery memory decreases with time; mechanically more complicated than hand-powered, some fluid contact components are not disposable
Mounted	Strong suction, adjustable vacuum power, disposable fluid contact components	Not portable, cannot be serviced in the field, no substitute power source

Types of Suctioning Catheters

Hard/Rigid Catheter	Soft Catheters
A large tube with multiple holes at the distal end	Long, flexible tube; smaller diameter than hard-tip catheters
Suctions larger volumes of fluid rapidly	Cannot remove large volumes of fluid rapidly
Standard size	Various sizes
Used in oropharyngeal airway only	Can be placed in the oropharynx, nasopharynx, or down the endotracheal tube
Removes larger particles	Suction tubing without catheter (facilitates suctioning of large debris)

Suctioning Techniques

- Wear protective eyewear, gloves, and face mask.
- Preoxygenate the patient.
- Determine depth of catheter insertion.
- With suction off, insert catheter.
- Turn on suction and suction while removing catheter (no more than 10 seconds).
- Hyperventilate the patient.

Tracheostomy suction technique

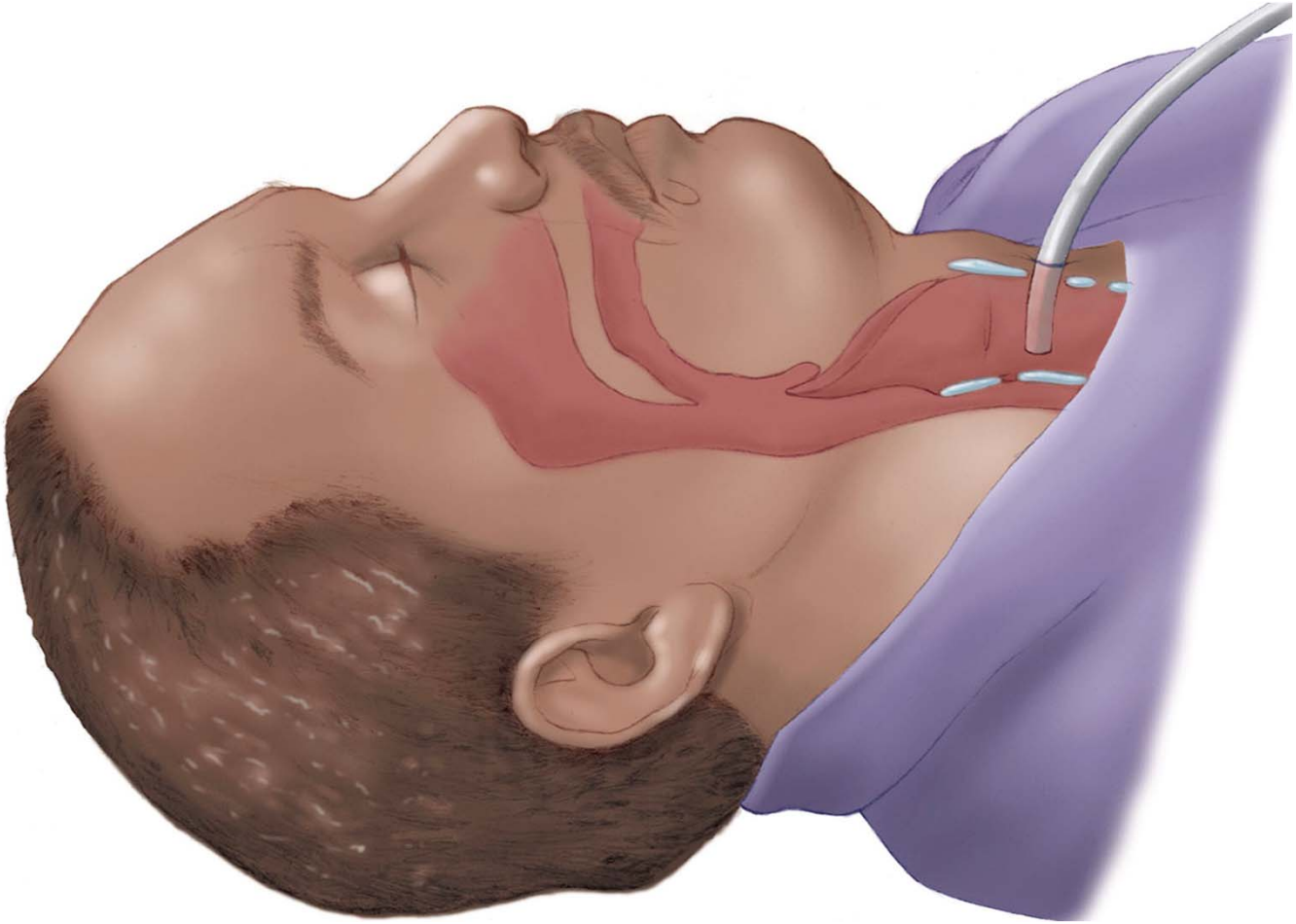

Gastric Decompression (1 of 3)

- Common problem with ventilating a nonintubated patient is gastric distention.
- Occurs when the procedure's high pressures trap air in the stomach.
- Once patient has gastric distention, you should place a tube in the stomach for gastric decompression, using either the nasogastric or orogastric approach.

Gastric Decompression (2 of 3)

To place a nasogastric or orogastric tube:

- Prepare patient's head in neutral position while preoxygenating.
- Determine length of tube insertion by measuring from the epigastrium to the angle of the jaw, then to the tip of the nares.
- If patient is awake, suppress the gag reflex with a topical anesthetic applied into the posterior oropharynx or with IV lidocaine.

Gastric Decompression (3 of 3)

- Lubricate the distal tip of the gastric tube and gently insert into the nares and along the nasal floor, or into the oral cavity at midline. Advance tube gently, and if patient is awake, encourage swallowing to facilitate tube's passage.
- Advance to predetermined mark on tube.
- Confirm placement.
- Apply suction and note gastric contents that pass through the tube.
- Secure the tube in place.

Oxygenation

Never withhold oxygen from any patient for whom it is indicated!

Oxygen Supply and Regulators

To calculate how long an oxygen tank will last:

<u>D cylinder tank life in minutes</u> =
(tank pressure in psi × 0.16) ÷ liters per minute

<u>E cylinder tank life in minutes</u> =
(tank pressure in psi × 0.28) ÷ liters per minute

<u>M cylinder tank life in minutes</u> =
(tank pressure in psi × 1.56) ÷ liters per minute

Oxygen Delivery Devices

Device	Oxygen Percentage
Nasal cannula	40%
Venturi mask	24, 28, 35, or 40%
Simple face mask	40 – 60%
Nonrebreather mask	80 – 95%

Ventilation Methods

- Mouth-to-mouth
- Mouth-to-nose
- Mouth-to-mask
- Bag-valve device
- Demand valve device
- Automatic transport ventilator

Bag-valve mask with built-in colorimetric $ETCO_2$ detector

Ventilation of Pediatric Patients

- Mask seal can be more difficult.
- Bag size depends on age of child.
- Ventilate according to current standards.
- Obtain chest rise and fall with each breath.
- Assess adequacy of ventilations by observing chest rise, listening to lung sounds, and assessing clinical improvement.

Demand valve and mask



Portable mechanical ventilator

Summary

- Respiratory Problems
- Respiratory System Assessment
- Airway Management

Today's Scenario

- You are called to the scene where you find a 65 year old male who keeps asking the same questions over and over again (e.g. "What did I eat for lunch today?").
- His wife says that she came home from work and found that he seemed to remember nothing other than events of many years ago.
- **He was completely normal this morning.**

Today's Scenario - Continued

- Medical History – None
- Medications – None
- Allergies – None
- V/S
  - Pulse: 72, Regular and strong
  - Respirations: 16 completely normal depth
  - BP: 120/80
  - SPO2: 98% on R/A
- Pupils: "PERRLA"

What might be going on here?

- Differential Diagnoses?
- What questions are you going to ask his wife?
- What are you going to assess?
- What are you going to do for this patient?
- What will the hospital do for this patient?

Transient Global Amnesia-“TGA”

- Sudden onset
- Negative neuro exam
- Often resolves itself within 24 hours
- No single cause can explain fully all the features of TGA

Transient Global Amnesia-“TGA”

- **Precipitants** of TGA frequently include:
- Physical exertion
- Overwhelming emotional stress
- Pain
- Cold-water exposure
- Sexual intercourse
- Valsalva maneuver
- These triggers may have a common physiologic feature: increased venous return to the superior vena cava
- Certain medications (sedatives)
- **No causative factors have been identified**